

**Safety Profile of *Citrullus mucospermus* Fursa Fruit in Wistar Rats and Characterization of Its Major Toxic Constituent**

Temitayo O. Ajayi* and Jones O. Moody

Department of Pharmacognosy, Faculty of Pharmacy, University of Ibadan, Nigeria.

ARTICLE INFO

Article history:

Received 05 April 2019

Revised 24 April 2019

Accepted 02 May 2019

Published online 07 May 2019

Copyright: © 2019 Ajayi and Moody. This is an open-access article distributed under the terms of the [Creative Commons Attribution License](https://creativecommons.org/licenses/by/4.0/), which permits unrestricted use, distribution, and reproduction in any medium, provided the original author and source are credited.

ABSTRACT

Citrullus mucospermus Fursa known as 'Egusi baara' in Southwest Nigeria is a pale yellow green bitter fruit used ethnomedicinally for hyperlipidemia and weight gain management. There, however, exist few references to the safety profile of *C. mucospermus* as it is known to contain toxic principles known as cucurbitacins. Hence, this study evaluated the safety profile of *C. mucospermus*, isolated and identified its major toxic cucurbitacin constituent.

The methanol extract of *C. mucospermus* at graded doses of 100, 200, 400 and 1000 mg/kg body weight was administered orally to five groups of rats for 28 days including a control on a daily basis. The biochemical, histopathological and hematological indices were evaluated using standard procedures. The isolated compound was obtained from the purification of the ethyl acetate fraction of the fruit extract and the characterization was by spectroscopic (IR, NMR) procedures.

An increase in neutrophil concentration after extract administration at a dose of 200 mg/kg was observed and a decrease in the liver enzymes at all doses tested confirming its hepatoprotective potential with mild to moderate changes observed in tissues of the kidney at 100 and 400 mg/kg and liver at all doses tested. The isolated compound was one of the toxic cucurbitacins identified as cucurbitacin E. The fruit pulp of *C. mucospermus* could offer hepatoprotective effects despite its cucurbitacin content.

Keywords: *Citrullus mucospermus*, cucurbitacin E, haemolysis, histopathology, neutrophil, haematology.

Introduction

Herbal medicine is an ancient form of management of several disease conditions. In recent times herbal medicine has enjoyed a reasonably high subscription due to its cost effectiveness, accessibility, as well as ease of adaptability to the people.¹ The World Health Organisation (WHO) affirmed that herbals are a major foundation for various drugs.²

A number of biological activities have been reported for *Citrullus* species by several researchers. These include anti-inflammatory, antioxidant and analgesic,^{3,4} antimicrobial,⁵ anti-prostatic and hyperplasia,⁶ anti-giardial⁵ and anti-diabetic activities.⁷ *Citrullus* species has particularly found relevance and reportedly used extensively in traditional medicine. The fruits are eaten as febrifuge when fully ripe or even when almost putrid.⁸ The root acts as a purgative and can serve as an emetic in high dose.⁸ The seed is used as demulcent and tonic.⁹ It is sometimes used in the treatment of the urinary tract infections⁸ as well as bed wetting.¹⁰ The fruit is known for its diuretic activity⁸ and valuable in the treatment of dropsy and renal stones.¹¹ The seed acts as an antihypertensive and also as a vermifuge. The fatty oil content as well as

aqueous and alcoholic extracts of the seed have been reported to paralyze worms especially tapeworms and roundworms.¹² The rind of the fruit is prescribed in cases of alcoholic poisoning and diabetes.⁹ *Citrullus mucospermus* is used as laxatives in the Northern Sudan where it found use also in the treatment of burns, swellings, rheumatism and gout.¹³ The fruits are used in Senegal as a strong purgative while it is used to treat diarrhea or gonorrhoea in Nigeria. Tar is extracted from the seeds and used for the treatment of scabies and skin tanning.¹³ The seed oil exhibits a better anthelmintic action than that of pumpkin seed oil.¹⁴

C. mucospermus is known to contain majorly cucurbitacins which are bitter-tasting principles that can also be isolated from other members of the Cucurbitaceae family. The occurrence of these constituents in the Cucurbitaceae species has been largely known to be in the roots and fruits of such plants. There are very few literature data on the safety profile of *C. mucospermus*¹ hence, the current study seeks to evaluate the in vivo toxicological potential of the methanol extract of *Citrullus mucospermus* whole fruit pulp and isolate its major constituent(s) in order to provide an insight to the effect of the plant material on medium to long term use.

Materials and Methods

General Experimental Procedures

The solvents used were of high quality (analytical grade) and include: Hexane, methanol, dichloromethane and ethyl acetate purchased from Sigma Co. USA.

A Bruker model AMX 400 NMR spectrometer operating on a standard pulse system was used to acquire ¹H and ¹³C-NMR and 2D spectra. The instruments ran at 400 MHz for ¹H while they ran at 125 and 100 MHz

*Corresponding author. E-mail: tayomiajayi@yahoo.com
Tel: +234(0) 7030308600

Citation: Ajayi TO and Moody JO. Safety Profile of *Citrullus mucospermus* Fursa Fruit in Wistar Rats and Characterization of Its Major Toxic Constituent. Trop J Nat Prod Res. 2019; 3(4):124-131. doi.org/10.26538/tjnpr/v3i4.4

Official Journal of Natural Product Research Group, Faculty of Pharmacy, University of Benin, Benin City, Nigeria.

for ^{13}C . CDCl_3 , was used as NMR solvent, and TMS was used as an internal standard. ESI-MS data were recorded on Thermo Orbitrap Fusion (Thermo Scientific). Mass was analyzed in Orbitrap (mass error on the instrument < 2 ppm). ESI-MS data were obtained on a Micromass Q-ToF micromass spectrometer. FTMS-ESI was analyzed on Thermo Orbitrap Fusion (Thermo Scientific). The IR was recorded on Agilent Technologies Cary 6030 Fourier Transform Infrared Spectrophotometer; $^1\text{H-NMR}$ (400 MHz, MeOD) and $^{13}\text{C-NMR}$ (125 MHz, MeOD) spectra were recorded on a Bruker AVANCE-400 spectrophotometer (Japan). The chemical shift values (δ) were reported in parts per million (ppm) relative to internal standard TMS and coupling constants (J values) were given in Hertz. TLC was performed on precoated silica gel GF254 plates and Column Chromatography was performed on silica gel (200–300 mesh) and Sorbadex-LH20 (Sorbent Technologies, Atlanta, GA, USA) with detection provided by UV light (254 and 366 nm) and by spraying with 1% vanillin- H_2SO_4 reagent followed by heating for 5-10 min (105 °C). A Gallenkamp electro thermal melting point apparatus was used to determine the melting point of isolated compound.

Collection and identification of the plant material

The whole fruits of *C. mucospermus* were collected from Ibadan City, Nigeria in May 2013. Authentication of the plant material was by Mr. Adeniji of the Forest Herbarium Ibadan where voucher specimen (FHI 110186) was also deposited.

Extraction

The whole fruits (4 kg) were cut into pieces and blended into a slurry and extracted by macerating in 95% methanol (5 L) for 72 h. Concentration of extract was done *in-vacuo* resulting in a yield 15.9 g (0.4%). A portion of the extract was reconstituted in 20% Tween 80.

Experimental animals

Twenty-five male Wistar rats with average weight of 140 g were obtained from the Experimental Animal House of the Faculty of Veterinary Medicine, University of Ibadan, Nigeria and kept under standard experimental conditions. They were divided into groups of five rats each ($n = 5$) with four experimental and one control group. The animals continued to feed on standard diet and clean water *ad libitum*. They were permitted to get accustomed to their new environment for two weeks before the experiment. They were fasted for 14 h all night before the experiment. The experimental protocol was in conformity with the Ethics Committee Guidelines of the University of Ibadan with ethical approval number (UI-ACUREC/17/0105) as well as the US guidelines of internationally accepted principles for laboratory animal use and care. Animals were also treated in agreement with OECD guidelines for testing of chemicals (NIH publication #85-23, 1985).

Treatment protocol

Experimental animals were grouped into 4 test groups and 1 control group of 5 rats each. Each dose was administered by oral gavage daily for 28 days and animals were observed daily till the end of the experiment.

Group 1: Animals were administered 100 mg/kg body weight of reconstituted methanol extract of *C. mucospermus* fruit daily.
Group 2: Animals were administered 200 mg/kg body weight of reconstituted methanol extract of *C. mucospermus* fruit daily.
Group 3: Animals were administered 400 mg/kg body weight of reconstituted methanol extract of *C. mucospermus* fruit daily.
Group 4: Rats were administered daily with 1000 mg/kg body weight of reconstituted methanol extract of *C. mucospermus* fruit daily.
Group 5: Control group administered with 20% Tween 80 made in distilled water on a daily basis.

Blood sample and organ collection

Capillary tubes were used to collect blood sample from the retro-orbital venous sinus of the rats into lithium heparinized bottles. The blood samples collected was centrifuged at 3000 rpm for 20 mins to obtain plasma which was stored at -20°C for biochemical assays. Hematological studies were carried out using the whole blood. The

kidney, liver, heart, spleen and lungs of the sacrificed animals were harvested and fixed in 10% formalin.

Biochemical assays

An auto-analyzer (ArchemBM240[®], Turkey) was used to assay biochemical indices which include: albumin,¹⁶ alkaline phosphatase (ALP),¹⁷ urea,¹⁸ aspartate aminotransferase (AST)¹⁹ and alanine aminotransferase (ALT).²⁰

Haematological assays

An automated haematology system analyzer (Archem BM240[®] Turkey) was used to assay White blood cell count (WBC), Red blood cell (RBC), Haemoglobin (HB), Haematocrit (HCT), Mean cell volume (MCV), and Mean corpuscular neutrophil (NEU).²¹

Histopathological Examination

The harvested organs were sliced. The formalin preserved tissues were dried out and treated with paraffin wax. A microtome was used to prepare sections and slice stained with hematoxylin-eosin before examination using a light microscope. Photomicrographs of the tissues were recorded.^{22,23}

Column chromatography of ethyl acetate fraction

The crude methanol extract of *Citrullus mucospermus* was subjected to vacuum liquid chromatography using hexane, dichloromethane, ethyl acetate and methanol in increasing polarities to elute. A total of 100 fractions were collected, monitored by TLC and fractions with similar TLC profile were pooled together.

Four pooled fractions 1-21 (hexane), 22-46 (dichloromethane), 47-55 (ethyl acetate) and 56 (aqueous/methanol). The aqueous/methanol fraction (most abundant 2.5 g) of the extract was then partitioned with ethyl acetate by solvent-solvent partitioning and the ethyl acetate partitioned fraction was adsorbed onto silica gel (230-400 mesh size), column and eluted with (100% dichloromethane and 5, 7, 10, 12, 15 and 20% methanol: dichloromethane mixtures in increasing polarities. Fractions (100 mL portions) were collected and fraction 15 (eluted with 100% (dichloromethane) was further purified using 1% methanol: dichloromethane on a silica gel purification column. This afforded an off white solid which gave a non-UV active spot that turned black on charring with 5% sulphuric acid in methanol. The isolated compound was characterized by spectroscopic means (IR, $^1\text{H-NMR}$, $^{13}\text{C-NMR}$ and MS).

Statistical Analysis

One-way analysis of variance (ANOVA) followed by Turkey's multiple comparison post-hoc test was used for data analysis. The disparity in the considered parameters between the control and the individual test groups were verified using the student t-test. Presentation of results was as mean \pm SEM. Considered significant differences were at $p < 0.05$.

Results and Discussion

Establishment of safety limits for prospective drugs are very imperative and are also frequently used to appraise possible health risk posed by plant extracts.²⁴ This study examined the effect of *C. mucospermus* extracts on hematological, histopathological and biochemical indices in Wistar rats. Observation from this study, reveals that the extract exhibited a better hepatoprotective activity at all tested doses when compared with the control group. Therefore, the management of acute liver and kidney disease where a decrease in biochemical indices is essential, may largely benefit from the polar extracts of *C. mucospermus*.

Prior to now, cucurbitacin E has been isolated from other related species and varieties of *Citrullus* as well as other plants from Cucurbitaceae family.²⁸ Plants with increased content of Cucurbitacins have been attributed to cross pollination with wild plants, stress during growth, such as inadequate water, poor fertilization or other conditions in cultivation practices. The consequence of this, may be critical, especially on a long term use of the plant extracts or consumption of the exceedingly bitter fruit.

The results agrees with previous work where at a maximum concentration of 200 mg/kg body weight, the safety evaluation studies revealed no toxicity in mice for the ethanol extract of the root.⁴

The safety profile observed in the methanol extract of the fruit demonstrated in this study may not be unconnected with possible ameliorative effect of other unidentified trace constituents present in the extract.

The present observation indicates that the crude methanol extract of *C. mucosospermus* is safe across board in all the doses tested and also confirms the ethnomedicinal claim of its use in weight control when compared to the control group as shown in Table 1.

Although previous researchers assessed the toxicity of cucurbitacins C, D, E, I and ascertained them to be lethal, toxic symptoms caused by these compounds have been reported to vary with animal species used, route of administration as well as quantity administered.^{29,31} The presence of a double bond at C-23 and acetyl group at C-25 have been found to augment the toxicity of cucurbitacins³⁰ which could account for its continuous use as food without constant toxicity reports.

Haematological parameters as shown in Table 2 revealed no significant difference ($p < 0.05$) across all indices observed, when compared to the control group.

Though there was an increase in white blood cells (WBC) and neutrophil, it was not statistically significant ($p > 0.05$) probably due to the ability of the plant to improve immunity as supported by reports from previous studies where the increase in WBC level was attributed to the effect of the saponin which is a phytochemical constituent of *Citrullus mucosospermus*. Saponins, which are reported to be suitable immunostimulators,^{25,26} could immensely elevate white blood cell levels. Biochemical parameters which are indicators of hepatic injury and hepatocellular necrosis²⁶ were significantly reduced with p-value at $p < 0.05$. AST, ALP and ALT were observed in test animals and compared to the control group at all doses tested.

Of note is the significant reduction in ALP ($p < 0.01$) at 400 mg/kg body weight and ($p < 0.05$) at 100 and 200 mg/kg body weight, respectively as shown in figure 3 which is indicative of the hepatoprotective potential of the extract. However, the reduction observed in BUN in all the test groups were not significant when compared to the control (Figure 4).

The decrease observed in ALT level was significant at $p < 0.05$ in the 400 mg/kg treated group as shown in figure 2 while a significant decrease at $p < 0.05$ in aspartate amino transferase (AST) was observed in the group of rats treated with 200 and 400 mg/kg of extract as shown in figure 1. The conferment of some protection on the liver and kidney is an advantage and made possible by a decrease in the liver enzymes. This is because an increase in enzyme level indicates some hepatic damage.²⁷

Histopathological examination however, revealed a mild to moderate change in test groups as shown in figures 6, 8 and 9 while figures 5 and 7 showed no changes in morphological cytoarchitecture of the heart and spleen, respectively which accounts for safety at all doses tested.

The morphological cytoarchitecture of the lungs of animals administered lower doses (200, 300 and 400 mg/kg body weight) of *Citrullus mucosospermus* fruit extract revealed no detectable lesions while a moderate alveolar interstitial congestion was observed in animals administered the highest dose tested (1000 mg/kg) which in turn may be said to be a dose-dependent observation as shown in figure 6.

The animals administered graded doses of the extract revealed a normal liver morphology when compared to the control group as shown in figure 9. A very mild diffuse degeneration of hepatocytes and a moderate periportal cellular infiltration by mononuclear cells was observed in rats treated with 100 mg/kg, while the hepatocytes appear diffusely shrunken and infiltrated in the 200 mg/kg treatment group, the group of animals treated with 400 mg/kg revealed a mild periportal cellular infiltration by mononuclear cells and a mild to moderate

Table 1: Determination of percentage mean weight increase in animals treated with *Citrullus mucosospermus* fruit extract.

Parameters	Grp 1+Cit 100 mg/kg	Grp 2+Cit 200 mg/kg	Grp 3+Cit 400 mg/kg	Grp4+Cit 1000 mg/kg	Control grp
Weight on purchase (g)	155.0±3.36	165.0±4.18	178.0±4.04	184.0±6.80	179.0±2.17
Weight before Experiment (g)	159.0±4.03	174.0±1.82	186.0±3.39	200.0±3.51	185.0±5.94
Weight after Experiment (g)	163.0±3.83	179.0± 7.87	192.0±5.02	210.0±8.86	205.0±6.64
% Difference in weight	2.51	2.87	3.22	5.00	10.81

Table 2: Effects of methanol extract of *Citrullus mucosospermus* fruit on hematological indices.

Parameters	<i>Citrullus mucosospermus</i> extract				
	Control	100 mg/kg	200 mg/kg	400 mg/kg	1000 mg/kg
PCV%	53.50 ± 0.71	46.00 ± 1.87	46.00 ± 2.83	47.33 ± 3.78	45.25 ± 3.20
Hb (g/dL)	17.50 ± 0.64	15.68 ± 0.88	15.30 ± 1.27	15.50 ± 1.17	14.82 ± 0.59
RBC (x 10 ⁶ /μL)	8.30 ± 0.60	7.59 ± 0.36	7.70 ± 0.29	8.22 ± 0.63	7.76 ± 0.68
WBC (x 10 ³ /μL)	6.32 ± 0.33	6.36 ± 1.78	5.44 ± 0.00	5.05 ± 6.22	5.61 ± 1.86
Plat (x 10 ³ /μL)	995 ± 8.17	1076 ± 0.42	895 ± 3.96	823 ± 1.06	947 ± 1.17
Lymp (%)	77.00 ± 2.83	75.00 ± 6.96	56.00 ± 32.52	75.33 ± 9.29	74.75 ± 9.21
Neut (%)	18.00 ± 16.8	17.40 ± 10.8	41.50 ± 33.23	21.00 ± 10.15	21.00 ± 9.86
Mono (%)	1.00 ± 0.00	1.80 ± 1.30	1.50 ± 0.71	1.00 ± 1.00	2.50 ± 1.29
Eosin (%)	1.50 ± 0.71	1.80 ± 1.09	1.00 ± 0.00	2.66 ± 0.57	1.75 ± 0.50

Values are Mean ± SEM (n = 5). Hb - Hemoglobin, Plat - Platelets, RBC - Red blood cell, WBC - White blood cell, LYMP - Lymphocytes, NEUT- Neutrophils. MONO - Monocytes, EOSIN - Eosinophil

periportal cellular infiltration by mononuclear cells in the group treated with 1000 mg/kg. All observed changes in the kidney, lungs and the liver were however, very mild to moderate and can be said to be possibly reversible with time.

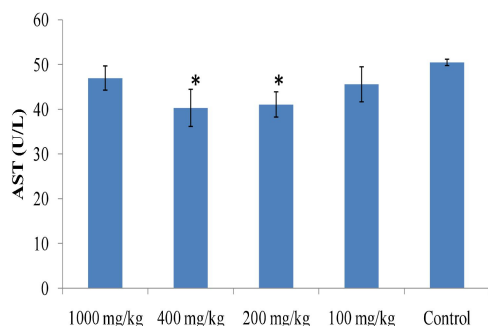


Figure 1: Effects of methanol extract of *Citrullus mucosospermus* fruit on Aspartate amino transferase. Values are presented as Mean \pm SEM (n = 5). *p < 0.05 as compared to the control.

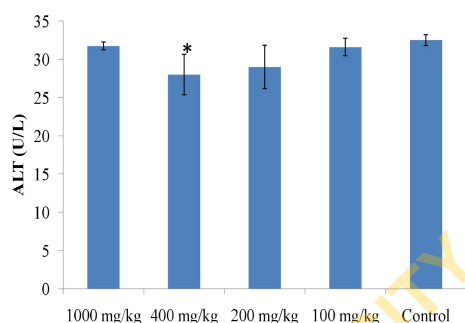


Figure 2: Effects of methanol extract of *Citrullus mucosospermus* fruit on Alanine amino transferase. Values are presented as Mean SEM (n = 5). *p < 0.05 as compared to the control.

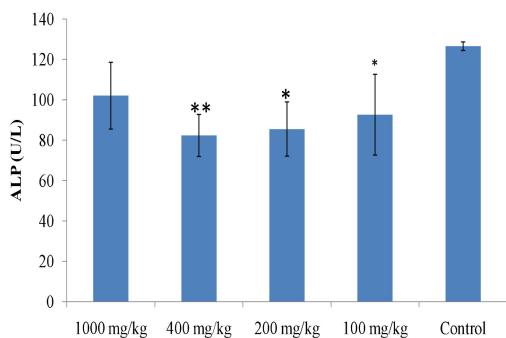


Figure 3: Effects of methanol extract of *Citrullus mucosospermus* fruit on Alkaline phosphatase. Values are presented as Mean SEM (n = 5). *p < 0.05, **p < 0.01 and as compared to the control and ***p < 0.001 as compared to the control.

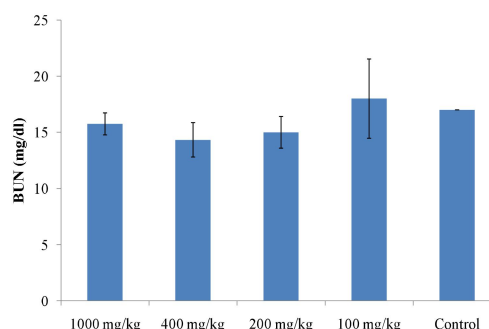


Figure 4: Effects of methanol extract of *Citrullus mucosospermus* fruit on Blood urea nitrogen. Values are presented as Mean SEM (n = 5).

The purification and isolation of constituent was by column chromatography (silica gel 230-400 mesh size; 1% methanol: dichloromethane mobile phase). The isolated constituent (Compound 1) in this study was obtained as an off-white powder (5 mg) identified as curcubitacin E (syn α -Elaterin) with an exact mass (ESI-MS) of 556.2341 (calculated mass 556.6024), R_f of 0.56 and melting point 232°C corresponding to a molecular formula $C_{32}H_{44}O_8$ with a chemical structure as shown in figure 10.

1H -NMR ($CDCl_3$, 500 MHz) δ ppm; 1.00 (s, 3H, H-18), 1.03 (s, 3H, H-19), 1.91 (m, 1H, H-7b), 1.25 (s, 3H, H-29), 1.35 (s, 3H, H-28), 1.40 (s, 3H, H-30), 1.45 (s, 3H, H-21), 1.5 (m, 1H, H-15b), 1.55 (s, 3H, H-6), 1.6 (s, 3H, H-27), 1.88 (m, 1H, H-15a), 2.0 (s, CH_3COO), 2.05 (m, 1H, H-8), 2.40 (m, 1H, H-7a), 2.50 (d, $J = 8.4$ Hz, 1H, 8H-17), 2.72 (d, $J = 9.6$ Hz, 1H, 12b), 3.22 (d, 1H, $J = 7.0$ Hz, H-12a), 4.38 (brs, 1H, H-16), 6.48 (d, $J = 4.0$ Hz, 1H, H-23), 7.05 (d, $J = 16.0$ Hz, 1H, H-24). IR (ν_{max} cm^{-1}): showed bands at 755.89, 1130.04, 1254.90, 1373.46, 1460.08, C=O (1688.90, 1729.13), CH stretches (2853.93, 2924.66) and OH (3424.52).

The ^{13}C -NMR spectra of compound 1 revealed the presence of three hydroxyl groups attached to carbon atoms C-2, C-16 and C-20. The signal of carbon 2, however appears more downfield at δ 144.5 (s) than normal as observed in the other two carbon atoms (C-16 and C-20 at δ 71.3 (d) and 78.2 (s) respectively) and this is due to the fact that the carbon 2 in question is also an olefinic carbon which makes the carbon to resonate at a frequency downfield. The downfield shift was also possible due to the proximity of the C-2 to a carbonyl group on C-3.

The ^{13}C -NMR signals at δ 198.7, δ 212.8 and δ 202.4 ppm are assignable to C-3, C-11 and C-22, respectively as they are relatively more deshielded than other carbons as a result of the presence of the carbonyl groups attached. The most deshielded carbon atom, which is C-11 (δ 212.8) ppm is probably due to the effect of angle strain on the cyclohexane ring on which it is located. This was closely followed by C-22 (δ 202.4) ppm whose chemical shift can be accounted for by the combination of inductive and anisotropic effects on the carbon atom. The presence of the carbonyl carbons were further confirmed by IR spectra with signal ν_{max} at 1729 cm^{-1} and 1688 cm^{-1} which are characteristic of carbonyl functional groups. Other signals in the IR spectra showed up at 2925 (saturated CH stretching), 2854, 1689, 1460, 1373, 1130, 755.89 cm^{-1} .

The presence of the hydroxyl groups were further confirmed in the IR spectra with absorption at ν_{max} 3424 cm^{-1} . which can also be accounted for in the 1H -NMR spectra with its proton assignable to proton 16 with signal showing downfield at 4.38 (br s). The spectra data of the compound was further confirmed by comparing with reported data from previous studies.³⁶

Evidence from 1H -NMR spectra with signals at 6.48 (d, 1H) and 7.05 (d, 1H) assignable to protons on C-23 and C-24. Although the signals appear in the aromatic region, the molecule is not aromatic in nature and

the downfield shifts of the protons can be accounted for by the presence of an α , β unsaturated lactone function, coupled with the anisotropic and the inductive effects on C-23 and C-24. This makes C-23 more electron rich and leaves C-24 electron deficient thereby allowing a more downfield shift of C-24 as compared to C-23 proton. This was further confirmed by the ^{13}C -NMR signals at δ 120.3 and 152.0 ppm assignable to C-23 and C-24 respectively. Protons on carbon 7, 12 and 15 are methylene protons. The protons on C-7 are shifted more downfield at δ 2.40 (m) and δ 1.91 (m) than normal due to their proximity to an olefinic group on C- 6. Protons on C-15 showed signals resonating at 1.88 (d) and 1.50 (d) which although is expected to be shifted more downfield

than protons on C-7 as revealed by its ^{13}C -NMR spectra showing a downfield shift at 45.5 (t). This may be due to spatial arrangement or conformation of the protons as supported by Seger *et al.*, 2005 which explained that the β configuration of protons on both C-7 and C-15 are shifted more downfield than the α configuration.³⁶ The protons on C-12 is a most deshielded CH_2 at 3.23 (d) and 2.73 (d) which was further confirmed by the signals in the ^{13}C -NMR spectra at the greatest downfield shift of δ 48.8 ppm. This may be due to the angle strain effect on the cyclohexane ring on which C-12 is located and also its proximity to the carbonyl group on C-11.

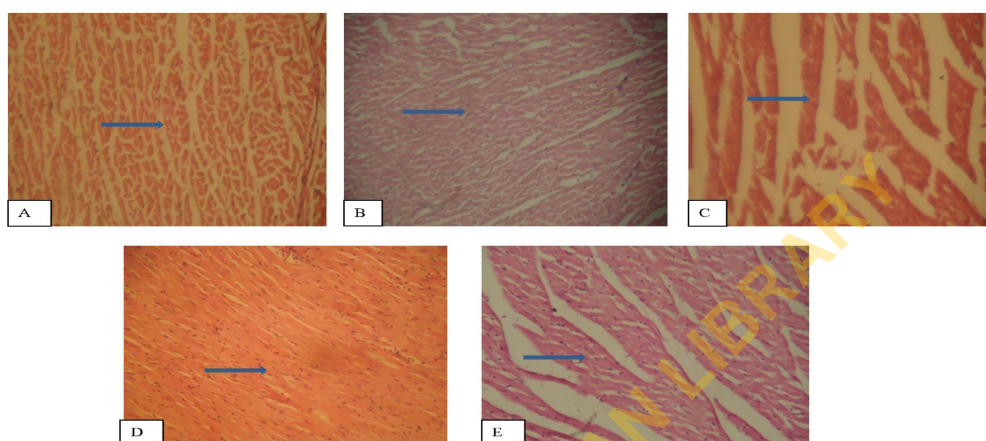


Figure 5: The photomicrograph and arrows showed normal morphological cytoarchitecture of rat heart administered graded doses of *Citrullus mucospermus* fruit extract when compared with the control group. A (100 mg/kg), B (200 mg/kg), C (400 mg/kg), D (1000 mg/kg), E (Control). Mag X40.

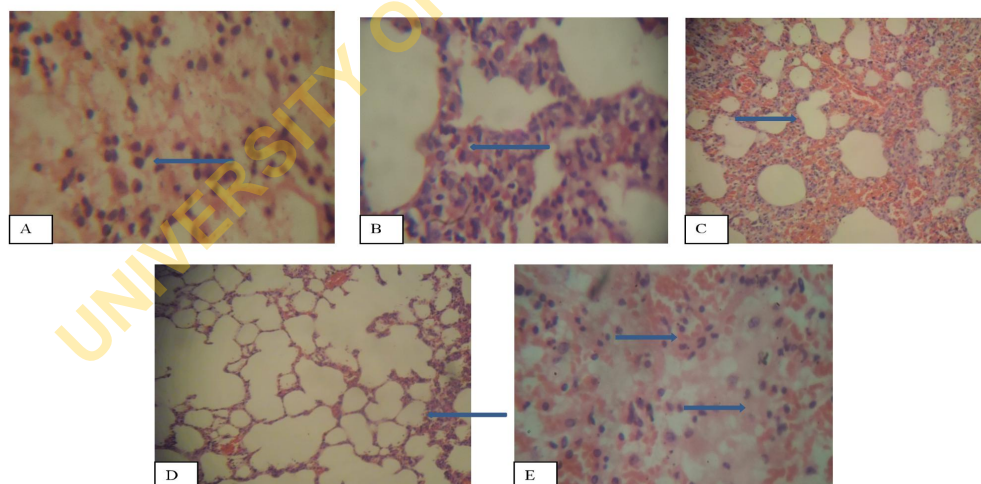


Figure 6: The photomicrograph showed no visible lesions in the morphological cytoarchitecture of rat lung administered lower doses of *Citrullus mucospermus* fruit extract when compared with the control group. However, there is a moderate alveolar interstitial congestion in animals treated with 1000 mg/kg. Arrows show areas of the rat lung comparing level of congestion at tested doses particularly as observed in group D. A (100 mg/kg), B (200 mg/kg), C (400 mg/kg), D (1000 mg/kg), E (Control). Mag X40.

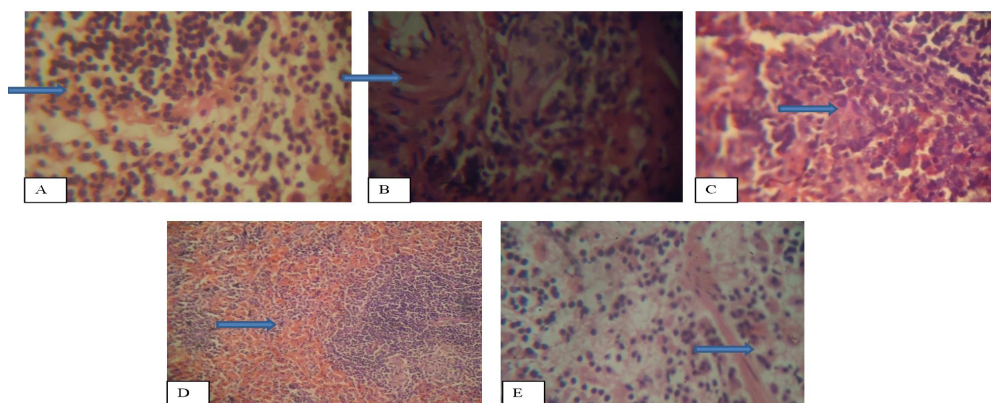


Figure 7: The photomicrograph showed normal morphological cytoarchitecture of rat spleen administered graded doses of *Citrullus mucospermus* fruit extract when compared to the control group. Arrows show points where there could possibly be congestion but appeared normal and comparable. A (100 mg/kg), B (200 mg/kg), C (400 mg/kg), D (1000 mg/kg), E (Control). Mag X40.

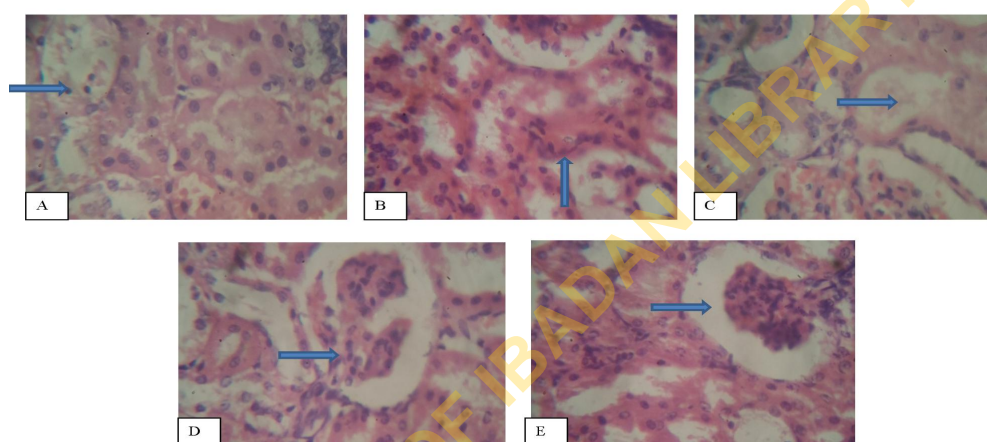


Figure 8: The photomicrographs revealed normal morphological cytoarchitecture of rat kidney administered graded doses of *Citrullus mucospermus* fruit pulp extract when compared to the control group. However, animals treated with 100 mg/kg, revealed a mild renal cortical congestion, periglomerular and interstitial cellular infiltration with a few tubules degenerated, having protein casts in their lumen. Also some tubules have a very scanty amount of pink staining material in the lumen in animals treated with 400 mg/kg of the extract. Arrows show points of congestion especially in the group A (100 mg/kg) and C (400 mg/kg) as different from clear points at the other doses. A (100 mg/kg), B (200 mg/kg), C (400 mg/kg), D (1000 mg/kg), E (Control). Mag X40.

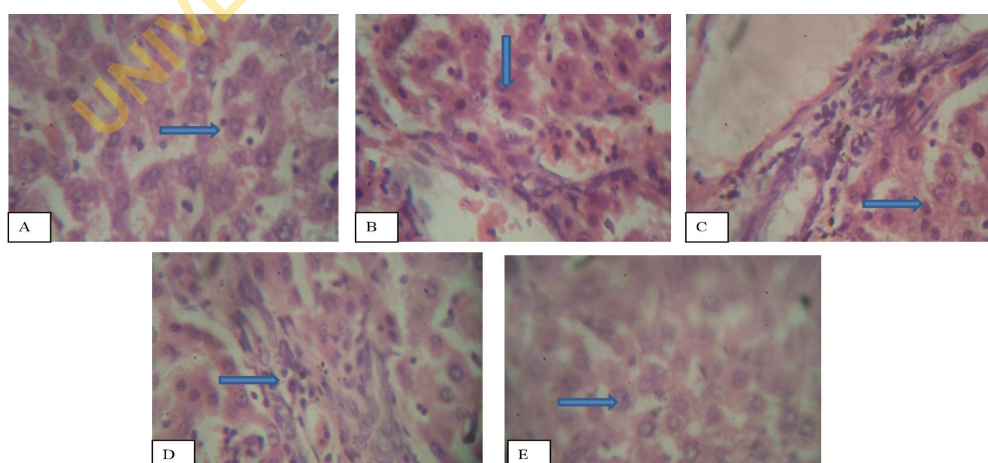
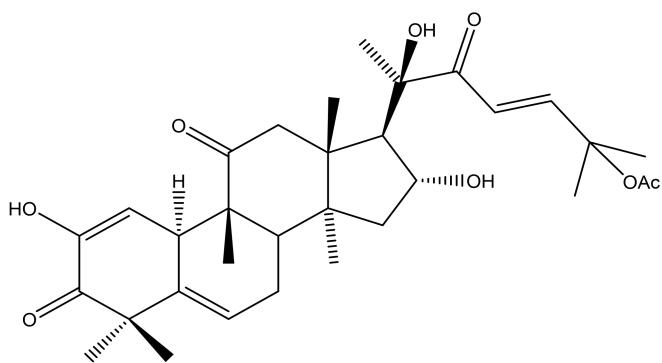


Figure 9: The photomicrographs and arrows showed normal morphological cytoarchitecture of rat liver administered graded doses of *Citrullus mucospermus* fruit pulp extract when compared to the control group. However, there is a very mild diffuse degeneration of hepatocytes and a moderate periportal cellular infiltration by mononuclear cells in A (100 mg/kg), the hepatocytes appear diffusely shrunken and infiltrated in B (200 mg/kg), there is a mild periportal cellular infiltration by mononuclear cells in C (400 mg/kg) and a mild to moderate periportal cellular infiltration by mononuclear cells in D (1000 mg/kg). A (100 mg/kg), B (200 mg/kg), C (400 mg/kg), D (1000 mg/kg), E (Control). Mag X40.

Table 3: ^{13}C -NMR data (δ ppm) of isolated compound 1 compared with already reported data of Cucurbitacin E.

Carbon no.	Compound 1 (CDCl ₃)	Curcubitacin E (CDCl ₃)
1	114.8	114.8
2	144.5	144.5
3	198.7	198.7
4	47.5	47.5
5	136.7	136.7
6	120.8	120.8
7	23.6	23.6
8	41.6	41.6
9	48.8	48.8
10	34.7	34.7
11	212.8	212.8
12	48.8	48.8
13	50.7	50.7
14	48.1	48.3
15	45.5	45.5
16	71.3	71.3
17	58.2	58.2
18	19.8	19.8
19	20.1	20.1
20	78.2	78.2
21	24.0	24.0
22	202.5	202.4
23	120.3	120.3
24	152.0	152.0
25	79.3	79.3
26	26.5	26.4
27	25.9	25.9
28	27.9	27.9
29	20.2	20.2
30	18.3	18.3
CH ₃ COO	170.3	170.3
CH ₃ COO	21.9	21.9

**Figure 10:** Molecular structure of Curcubitacin E.

Conclusion

This study revealed safety at all doses tested in the heart and spleen tissues of tested animals although with possible reversible mild to moderate non-lethal changes in organs such as the kidney and liver at particular doses tested. This may be due to deposition of high content of the toxic principle cucurbitacin E at the tissue sites. Nonetheless, the fruit pulp extract of *C. mucospermus* has proven to be capable of improving immunity and lowering the biochemical indices thereby can be said to be potentially hepatoprotective.

The isolation and characterization of the compound revealed as cucurbitacin E, a major toxic constituent in *C. mucospermus* has been isolated from other related species and varieties of *Citrullus* as well as other plants from Cucurbitaceae family but this study is the first report of isolation of cucurbitacin E from *C. mucospermus*.²⁸ However, other isolated constituents with R_f ranging from 0.68 and 0.47 were in trace amounts with yields rather too small for further spectroscopic characterization.

Conflict of interest

The authors declare no conflict of interest.

Authors' Declaration

The authors hereby declare that the work presented in this article is original and that any liability for claims relating to the content of this article will be borne by them.

Acknowledgments

The authors are grateful to the Federal Government of Nigeria for the TETFUND grants to travel to complete this work and also to Dr. 'Sanmi Aina of the Faculty of Veterinary Medicine, University of Ibadan for technical support with sample preparation and interpretation.

References

1. Aliyu R, Adebayo AH, Gatsing D. The effects of the ethanolic extract of *Commiphora africana* (Bursaceae) on rat liver and kidney functions. *J Pharmacol Toxicol.* 2007; (2):373-379.
2. Doughari JH, El-Mahmood AM, Tyoyina I. Antimicrobial activity of leaf extracts of *Senna obtusifolia* (L). *Afr J Pharm Pharmacol.* 2008; (2):7-13.
3. Gill NS, Bansal RK, Garg MS. Evaluation of antioxidant, anti-inflammatory and analgesic potential of *Citrullus lanatus* seed extract in rodent model. *The Int J Nutr and Wellness* 2010; 9:2.
4. Madhavi P, Maruthi R, Kamala V. Evaluation of anti-inflammatory activity of *Citrullus lanatus* seed oil by *in-vivo* and *in-vitro* models. *Int Res J Pharm App Sci.* 2012; (2):104-108.
5. LoiyElsir AH, Hasnah MS, Sakina MA. *In vitro* Antimicrobial activities of chloroformic, hexane and ethanolic extracts of *Citrullus lanatus* var *Citroides* (wild melon). *J Med Plants Res.* 2011; (5):1338-1344.
6. Adesanya AO, Olaseinde OO, Oguntayo OD. Effects of methanolic extracts of *Citrullus lanatus* seed on experimentally induced prostatic hyperplasia. *Eur J Med Plants* 2011; 1:171-179.
7. Jiyun A, Wonhee C, Suna K. Anti-diabetic effect of watermelon (*Citrullus vulgaris* Schrad) on streptozotocin-induced diabetic mice. *Food Sci Biotech* 2011; 20:251-254.
8. Grieve M and Leyel CF. *A Modern Herbal: The Medicinal, Culinary, Cosmetic, and Economic Properties, Cultivation, and Folklore of Herbs, Grasses, Fungi, Shrubs, and Trees with All Their Modern Scientific Uses*, Published by Penguin (1980).

9. Duke JA and Ayensu ES. Medicinal plants of china, Reference publication. Inc, ISBN, 0- 917256, 20:4, 1985.
10. Moerman DE. Native American Ethnobotany: Timber Press 1998 ISBN-10: 0881924539 ISBN-13: 9780881924534.
11. Chiej R. Encyclopedia of medicinal plants. MacDonald 1984; ISBN 0-35610541-5.
12. Chopra A, Kaur N, Lali T. Herbal Drug- A promising Approach to Obesity Management. J Res Pharm Sci. 2014; 2:1-5.
13. Schippers RR and Budd L. African indigenous vegetables. Rome: IPGRI, and England: Nat Res Inst. 1997.
14. Jackson WPU. Origins and meanings of names of South African plant genera. University of Cape Town 1990.
15. Celikel N and Kavas G. Antimicrobial properties of some essential oils against some pathogenic microorganisms. Czech J Food Sci 2008; 26:174-181.
16. Doumas BT, Perry BW, Sasse EA. Standardization in bilirubin assays: Evaluation of selected methods and stability of bilirubin solutions. Clin Chem. 1973; 19:984-993.
17. Tietz NW, Rinker AD, Shaw LW. International Federation of Clinical Chemistry, IFCC methods for the measurement of catalytic concentration of enzymes, Part 5. IFCC method for alkaline phosphatase (orthophosphoric-monoester phosphohydrolase, alkaline optimum, EC 3.1.3.1) J Clin Chem Clin Biochem. 1983; 21:731-748.
18. Kreig M, Gunsser KJ, Steinhagen-Thiessen E. Comparative quantitative clinic-chemical analysis of the characteristics of 24- hour urine and morning urine. J Clin Chem. Clin Biochem. 1986; 24:863-869.
19. Bergmeyer HU, Horder M, Rej R. International Federation of Clinical Chemistry Scientific Committee, Analytical section: Approved recommendation (1985) on IFCC methods for the measurement of catalytic concentration of enzymes. Part 2, IFCC method for aspartate aminotransferase (L-aspartate: 2-oxoglutarate aminotransferase, EC 2.6.1.1). J Clin Biochem 1986a; 24:497-510.
20. Bergmeyer HU, Horder M, Rej R. International Federation of Clinical Chemistry Scientific Committee, Analytical section: Approved recommendation (1985) on IFCC methods for the measurement of catalytic concentration of enzymes. Part 3, IFCC method for alanine aminotransferase (L-alanine: 2-oxoglutarate aminotransferase, EC 2.6.1.2). J Clin Biochem. 1986b; 24:481-495.
21. Baker FJ, Silverston RE, Pallister CJ. Baker and Silverston's Introduction to Medical Laboratory Technology, 7th ed. 1998; 356-360.
22. OECD [Organisation for Economic Co-operation and Development]. Guideline 1992, 420. Acute oral toxicity—Fixed dose procedure. Paris: OECD.
23. Charity UO, Uwaifoh A, Charles II. The effect of chronic ingestion of crude *Garcinia kola* on the histology of liver. Eur J Exp Biol. 2012; 2:404-409.
24. Klassen CD and Eaton DL. Principles of toxicity the basic science of poisons, 4th ed. Pergamon, Elmsford 1991; 12-50.
25. James SL and Pearce EJ. The influence of adjuvant on induction of protective immunity by a nonliving vaccine against Schistosomiasis. J Immunol 1988; 140: 2753.
26. Campbell JB. Saponins-adjuvants: Theory and practical applications, Edited by DES Stewart-Tull, Chapter 4, (In press). Butterworth Heinemann Inc. Toronto 1993.
27. Rej R. Aminotransferase in disease. Clin Lab Med. 1989; 9:667-687.
28. Abdelwahab SI, Hassan LE, Sirat HM, Yagi SM, Koko WS, Mohan S, Taha MM, Ahmad S, Chuen CS, Narrima P, Rais MM, Hadi AH. Anti-inflammatory activities of cucurbitacin E isolated from *Citrullus lanatus* var. citroides: role of reactive nitrogen species and cyclooxygenase enzyme inhibition. Fitoterapia. 2011; 82(8):1190-1197.
29. Njoroge GN and Leonard EN. Edible and poisonous species of cucurbitaceae in the central highlands of Kenya. J East Afr Nat Hist. 1994; 83:101-115.
30. Storrs AE, Pearce GD Ndola. Zambia: Forest Department; Don't Eat These: A Guide to some local poisonous plants 1982.
31. Yaowalak U, Usaneeporn L, Weena J, Tanawan K. Immunosuppressive effects of Cucurbitacin B on human peripheral blood lymphocytes. J Med Plants Res. 2010; 4:2340-2347.
32. Ajuru MG and Okoli BE. The Morphological characterization of the Melon Species in the Family Cucurbitaceae Juss, and their utilization in Nigeria. Int J Mod Bot 2013; 3:15-19.
33. Butani DK and Verma S. Insect pests of vegetables and their control- Drumsticks. Pesticides 1981; 15:29-32.
34. Chopra RN, Nayar SL, Chopra IC. Glossary of Indian Medicinal plants, Council of Scientific and Research. New Delhi. 1956.
35. Musza LL, Speight P, McElhiney S, Barrow CJ, Gillum AM, Cooper R. Cucurbitacins, cell adhesion inhibitors from *Conobea scoparioides*. J Nat Prod. 1994; 57:1498-1502.
36. Seger C., Sturm S., Mair M.-E., Ellmerer EP, Stuppner H. ¹H and ¹³C-NMR signal assignment of cucurbitacin derivatives from *Citrullus colocynthis* (L.) Schrader and *Ecballium elaterium* L. (Cucurbitaceae), Magn Reson Chem 2005; 43:489-491.