

See discussions, stats, and author profiles for this publication at: <https://www.researchgate.net/publication/316499892>

Ameliorative Effects of Methanolic Extract of *Ficus exasperata* (Vahl.) on Carbon Tetrachloride-Induced Hepatopathy in...

Article · January 2017

DOI: 10.5455/jib.20170423062146

CITATIONS

0

READS

8

3 authors, including:



A.O. Adeyi

University of Ibadan

14 PUBLICATIONS 59 CITATIONS

SEE PROFILE

University of Ibadan Library



Ameliorative effects of methanolic extract of *Ficus exasperata* (Vahl.) on carbon tetrachloride-induced hepatopathy in albino rats

Akindele Oluwatosin Adeyi¹, Blessing D. Akwarandu¹,
Esther Olubisi Adeyi²

ABSTRACT

Aim/Background: This study investigated the ameliorative potentials of methanol leaf extract of *Ficus exasperata* against carbon tetrachloride induced hepatopathy in rats. **Methods:** A total of 30 adult male Wistar strain albino rats divided into five treatments and one control groups were used for the study. Hepatopathy was induced in four of the experimental groups (Group B-E) by a single intraperitoneal injection of 0.4 ml of carbon tetrachloride (CCl₄) dissolved in paraffin wax. Groups B-D were thereafter treated with 100, 200 and 300 mg/kg of the extract daily for 7 days while Group E was the positive control. **Results:** Administration of CCl₄ induced hepatopathy in all exposed rats as indicated by significantly higher ($P < 0.05$) serum concentrations of liver enzymes (alanine transaminase, aspartate transaminase, alkaline phosphatase, and gamma-glutamyltransferase) compared to the pre-treatment levels and the control rats. Untreated hepatopathy caused progressive reduction in food consumption with concomitant reduction in body weight, acute anemia, hypohemoglobinemia, thrombocytopenia, increased oxidative stress biomarkers and diffuse vacuolation of the hepatocytes. Treatment with the extract however attenuated the liver damage by significant reduction in serum liver enzymes concentrations to levels comparable to the control rats. Similarly, treated rats showed a significant increase ($P < 0.05$) in weight gain, improved hematological parameters, reduction in oxidative stress biomarkers and amelioration of various hepatic degenerations. The presence of vitamins B and C, flavonoids, tannins, alkaloids and various minerals with antioxidizing potentials in the methanolic extract of *F. exasperata* might have accounted for the observed ameliorative properties through free radical scavenging. **Conclusion:** We, however, suggest further studies to isolate and characterize the components in the plants responsible for these properties.

KEY WORDS: Ameliorative, antioxidant profile, carbon tetrachloride, *Ficus exasperata*, hepatopathy, liver enzymes

¹Department of Zoology, Animal Physiology Unit, University of Ibadan, Nigeria, ²Department of Biochemistry, Federal University of Agriculture, Abeokuta, Nigeria

Address for correspondence: Akindele Oluwatosin Adeyi, Department of Zoology, Animal Physiology Unit, University of Ibadan, Nigeria. E-mail: delegenius@yahoo.com

Received: October 13, 2016

Accepted: March 09, 2017

Published: April 24, 2017

INTRODUCTION

The liver is an important organ involved in the maintenance of metabolic functions and detoxification of exogenous and endogenous challenges [1]. These vital roles make the liver highly exposed and susceptible to toxic agents, which may result in impairment of its functions thereby affecting diverse homeostatic mechanisms with potentially serious consequences [2]. Liver disease is a worldwide health problem accounting for about 20,000 deaths annually [3] and one major cause of liver disease is industrial exposure to hepatotoxic chemical of which carbon tetrachloride (CCl₄) is a major culprit [4].

CCl₄ is a widely used industrial chemical and a potent hepatotoxin. Liver damage following exposure to CCl₄

occurs after 24 h and results in painful swollen liver, ascites, hemorrhages, hepatic-induced coma, and death [5]. The hepatotoxicity of CCl₄ results from the metabolism of CCl₄ to the trichloromethyl free radical (CCl₃·) by the nicotinamide adenine dinucleotide phosphate (NADPH)–cytochrome P450 system, transferring an electron from NADPH to CCl₄ [6,7]. This free radical thus formed and related reactive species induce cellular damage by initiating lipid and protein peroxidation, covalently binding to protein, causing a rise in intracellular Ca²⁺, depleting GSH, or reducing iron, ultimately leading to cell death [8,9]. Rapid, extensive lipid peroxidation of the membrane lipids has been proposed as the basis of CCl₄ hepatocellular toxicity [6]. Treatment with plants extract rich in antioxidants have therefore been reported to protect against liver damage caused by CCl₄.

Ficus exasperata (Vahl), commonly called sandpaper tree is a plant rich in chemical constituents with antioxidizing potentials [10,11]. The leaves, stem bark, roots, flowers, and seeds of plants have been utilized in various forms for the treatment of diverse diseases. Root decoctions are taken for the treatment of urinary tract ailments, gonorrhoea, asthma and tuberculosis and chewed in case of cough [12-14]. The leafy shoot is used in preparations applied externally against jaundice or drunk as a diuretic. Leaf pulp or sap is externally applied for the treatment of rash, wounds, leprosy sores, fungal infections, itching, edema, ringworm, rheumatism, and lumbar and intercostal pain. The powder of the dried leaf is sprinkled on burns [15]. The young leaf is chewed and swallowed in case of gastric ulcers. The leaf juice or a decoction of the leaf is used for the treatment of stomach-ache, as an antidote to poison and for the treatment of diseases of the liver, kidneys, and urinary tract [16].

Few researches have investigated the hepatoprotective potentials of several plants extract on carbon tetrachloride-induced hepatopathy [17-20]. There is, however, paucity of information on the ameliorative activities of plants extract on CCl₄-induced hepatopathy. This study therefore investigated the ameliorative activity of methanolic leaf extract of *F. exasperata* on CCl₄ induced hepatopathy in albino rats.

MATERIALS AND METHODS

Collection of Plant Materials and Preparation of Extract

Fresh leaves of *F. exasperata* were collected within the campus of the University of Ibadan, Ibadan. The plant was authenticated at the University of Ibadan Herbarium where voucher specimen with voucher number UIH-22438 was kept. The leaves were air-dried at room temperature (27°C ± 2°C). And then blended into powdery form using Nakai blender (China). 100 g of the blended leaves was then soaked in 1 L of Methanol for 48 h. The extracts were drained and the solvent was left to evaporate at room temperature to dryness. The dried extract yielded 13 g (w/w) and was stored in the refrigerator at 4°C. Dilution to desired concentrations with distilled water was done when needed. The diluted extracts were administered orally to the rats daily for 7 consecutive days.

Qualitative and Quantitative Phytochemical Screening of the Extract

Qualitative phytochemical screening of the methanol leave extract of *F. exasperata* was carried out according to the methods described by Trease and Evans [21] for the detection of saponins, tannins, alkaloids, flavonoids, steroid, and phenol. Quantitative phytochemical analysis was determined using [22] methods.

Vitamins and Minerals Analyses

The concentrations of chromium, magnesium, calcium, zinc, vitamins B complex and vitamin C in extract were determined using methods described by Association of Official Analytical Chemists [22].

The Experimental Animals

A total of 30 adult male Wistar rats (weight = 140-152 g) were obtained from the Veterinary Department, University of Ibadan, Ibadan. They were acclimatized at the animal house of the Department of Zoology, University of Ibadan in cages at room temperature (27°C ± 2°C) for 14 days. They were given rat feed and water *ad-libitum*. The experiment was performed in accordance with the National Institute of Health guidelines of care and use of laboratory animals.

Experimental Grouping

The animals were sorted into six groups of five rats each (based on their body weights) [Table 1]:

Induction of Hepatopathy

Hepatoapthy was induced in rats by a single intraperitoneal injection of 0.4 ml/kg body weight of CCl₄ dissolved in paraffin wax. Blood was collected from each rat by ocular puncture prior and after induction for the estimation of liver enzymes.

Blood Collection, Dissection, and Collection of Organs

At the end of treatment, blood was collected from each surviving rat by ocular puncture into properly labeled lithium heparin bottles. The animals were then sacrificed by cervical dislocation. The liver of each rat was then collected, stored in 10% formalin and processed routinely for further histopathological studies.

Liver Function Estimation

The concentrations of alkaline phosphatase (ALP), gamma-glutamyltransferase (GGT), alanine transaminase (ALT), aspartate transaminase (AST) in the plasma were determined using assay kits from Roche Diagnostics on Roche modular (model P800 Mannheim, Germany) according to Tietz *et al.* [23].

Hematological Studies

The packed cell volume (PCV) was determined using the centrifuge and microhematocrit reader. The total hemoglobin (Hb) concentration was estimated using the cyanomethemoglobin method. The total white blood cell

Table 1: Experimental groups of induced and treated rats

| Groups | Number of rats | CCl ₄ induction | Treatment with <i>F. exasperata</i> |
|--------|----------------|----------------------------|-------------------------------------|
| A | 5 | None | None |
| B | 5 | Induced | 100 mg/kg |
| C | 5 | Induced | 200 mg/kg |
| D | 5 | Induced | 300 mg/kg |
| E | 5 | Induced | None |
| F | 5 | None | 200 mg/kg |

Body weights of the animals in each of the groups were taken and recorded. CCl₄: Carbon tetrachloride, *F. exasperata*: *Ficus exasperata*

(WBC) count and differentials, red blood cell (RBC) count, platelets count, mean cell hemoglobin (MCH), mean cell volume (MCV), and MCH concentration (MCHC) were also determined.

Enzyme Assay

The plasma concentrations of the antioxidant enzymes; catalase, peroxidase, and superoxide dismutase (SOD) as well as the total antioxidant potential (TAP) and total plasma peroxidase (TPP) were determined using the spectrophotometer.

Statistical Analysis

Data obtained were expressed as mean \pm standard error. Significant difference between test and control groups were tested using ANOVA and Duncan mean test at $P < 0.05$, using the SPSS computer software, version 17.0.

RESULTS

Minerals, Vitamins and Phytochemical Analyses of *F. exasperata*

The concentrations of minerals and vitamins in the methanol leaf extract of *F. exasperata* are: 1.421 mg/g (calcium), 0.015 mg/g (chromium), 1.122 mg/g (magnesium), 0.131 mg/g (zinc), 8.36 mg/dg (vitamin C) and 0.812 mg/dg (vitamin B), while percentage composition of phytochemicals are 0.60% (alkaloids), 0.001% (tannins), 0.55% (saponin), 0.94% (phenols), 0.72% (steroid) and 0.20% (flavanoid).

Table 2: Minerals, vitamins and phytochemical analyses of *F. exasperata*

| Chemical components | <i>F. exasperata</i> |
|---------------------|----------------------|
| Calcium (mg/g) | 1.421 \pm 0.02 |
| Chromium (mg/g) | 0.015 \pm 0.01 |
| Magnesium (mg/g) | 1.122 \pm 0.42 |
| Zinc (mg/g) | 0.131 \pm 0.07 |
| Vitamin C (mg/dg) | 8.36 \pm 0.31 |
| Vitamin B (mg/dg) | 0.812 \pm 0.42 |
| Alkaloids (%) | 0.60 \pm 0.1 |
| Tannin (%) | 0.001 \pm 0.01 |
| Saponin (%) | 0.55 \pm 0.1 |
| Phenol (%) | 0.94 \pm 0.3 |
| Steroid (%) | 0.72 \pm 0.2 |
| Flavanoid (%) | 0.20 \pm 0.1 |

F. exasperata: *Ficus exasperata*

Body Weight

Mean body weight of the rats before injection of CCl₄ ranged between 155 and 163 g [Figure 1]. There was however marked reduction in body weight of the animals after CCl₄ injection with mean body weight dropping to between 140 and 148 g. Treatment with *F. exasperata* for 7 days increased mean body weight by 2.76, 3.75 and 2.06% in rats treated with 100, 200 and 300 mg/kg, respectively. Further drop in body weight was recorded in the untreated group.

Liver Enzymes

The concentrations of AST, ALT, ALP and GGT were not significantly different ($P < 0.05$) in all groups before injection of CCl₄ [Table 3]. Injection with CCl₄ resulted in significant increase ($P < 0.05$) in the concentrations of all the liver enzymes compared to the pre-induction values and the control rats. Treatment with various doses of the plant extract, however, caused dose-dependent reduction in the plasma concentrations of the enzymes. The positive control (Group E) had the highest concentrations of all the assayed enzymes compared with the treated and control rats. Comparing the effectiveness of the different doses of the extract, the result showed that treatment with 300 mg/kg of the extract produced the best ameliorative effect as indicated by the lowest concentrations of the liver enzymes in the plasma.

RBC Indices

The values of PCV, RBC, Hb, and platelets were significantly higher ($P < 0.05$) in rats treated with various doses of the plant extract than the positive control rats [Table 4]. Among the treated groups, rats treated with the highest dose (300 mg/kg) had highest levels of PCV, Hb, RBC and platelets than other treated groups. However, the MCHC, MCV, and MCH values of all the experimental groups were not significantly different.

WBC and Differentials

Counts of WBC, lymphocyte, neutrophils and monocytes were significantly lower ($P < 0.05$) in the control rats than all treatment groups [Table 5]. Rats of the positive control group (Group E) had significantly higher ($P < 0.05$) counts of WBC, lymphocyte, neutrophils and monocytes compared to rats treated with various doses of the plant extract. Treatment with various doses of the extract, however, did not cause a dose-dependent alteration in the counts of WBC, lymphocyte, neutrophils and monocytes among the treated groups. Rats

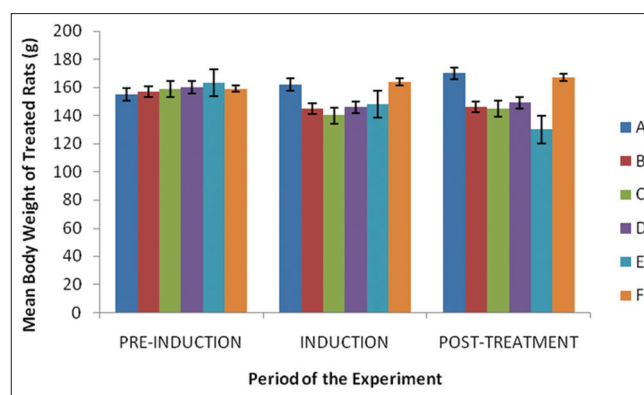


Figure 1: Body weight of carbon tetrachloride (CCl₄)-injected rats treated with *Ficus exasperata*. Group A: Control, Group B: CCl₄ injected and treated with 100 mg/kg of the extract, Group C: CCl₄ injected and treated with 200 mg/kg of the extract, Group D: CCl₄ injected and treated with 300 mg/kg of the extract, Group E: Group injected with CCl₄ only, Group F: Group treated with 200 mg/kg of the extract

Table 3: Effects of methanolic leaf extract of *F. exasperata* on the concentrations of liver enzymes

| Groups | AST (IU/L) | | ALT (IU/L) | | ALP (IU/L) | | GGT (IU/L) | |
|--------|-----------------------|-----------------------|-----------------------|-----------------------|-----------------------|-------------------------|-----------------------|-----------------------|
| | Pre-induction | Post-treatment | Pre-induction | Post-treatment | Pre-induction | Post-treatment | Pre-induction | Post-treatment |
| A | 43.2±2.9 ^a | 42.5±1.2 ^a | 31.2±1.0 ^a | 31.8±0.8 ^a | 82.2±3.2 ^a | 84.0±7.6 ^a | 1.5±0.2 ^a | n.d. |
| B | 44.1±1.2 ^a | 42.5±2.1 ^a | 33.8±2.4 ^a | 31.0±1.0 ^a | 84.3±2.1 ^a | 110.8±9.2 ^b | 1.45±0.2 ^a | 3.2±0.2 ^a |
| C | 43.5±4.5 ^a | 41.8±1.2 ^a | 34.4±1.5 ^a | 30.0±1.4 ^a | 83.1±5.5 ^a | 134.2±6.4 ^b | 1.7±0.3 ^a | 4.3±0.2 ^a |
| D | 44.5±2.2 ^a | 40.2±1.0 ^a | 32.9±2.2 ^a | 29.0±0.8 ^a | 83.2±5.4 ^a | 154.7±2.5 ^{bc} | 1.7±0.7 ^a | 3.7±0.9 ^a |
| E | 44.5±5.9 ^a | 60.0±2.8 ^b | 32.2±4.2 ^a | 59.0±1.1 ^b | 82.0±3.3 ^a | 144.3±5.1 ^{bc} | 1.4±0.6 ^a | 3.8±1.91 ^a |
| F | 43.9±1.2 ^a | 44.0±2.0 ^a | 31.2±2.6 ^a | 30.3±1.6 ^a | 84.8±8.6 ^a | n.d. | 1.6±0.3 ^a | n.d. |

Values are mean±SE, $n \leq 5$. Values within a column having different superscripts are significantly different at $P < 0.05$. n.d: Not determined, SE: Standard error; ALP: Alkaline phosphatase,

ALT: Alanine transaminase, AST: Aspartate transaminase, GGT: Gamma-glutamyltransferase, *F. exasperata*: *Ficus exasperata*, CCl₄: Carbon tetrachloride, Group A: Control, Group B: CCl₄ injected and treated with 100 mg/kg of the extract, Group C: CCl₄ injected and treated with 200 mg/kg of the extract, Group D: CCl₄ injected and treated with 300 mg/kg of the extract, Group E: Group injected with CCl₄ only, Group F: Group treated with 200 mg/kg of the extract

treated with the extract alone (Group F) had significantly lower counts than the positive control group.

Antioxidant Profile

Rats in the control group recorded the lowest concentrations of catalase, SOD, TPP and oxidative stress index compared to the treated and positive control groups [Table 6]. The concentrations of all antioxidant enzymes were highest in the positive control rats (Group E). All groups treated with the extract had significantly lower concentrations of the enzymes compared to the untreated groups, although treatment with the various doses of the extract did not induce a dose-dependent change in the concentrations of the antioxidant enzymes. Rats administered the plant extract alone (Group F) had significantly lower ($P < 0.05$) concentrations of the enzymes than the untreated group. The value of the TAP was lowest in the positive control rats and highest in rats administered the extract alone. Treatment with various doses of the extract induced a dose-dependent increase in the value TAP among the treated groups.

Histopathological Study

The slides of the liver of the treated and untreated rats are presented in Plate 1a-f. The liver of the control rats [Plate 1a], rats administered with 200 mg/kg of the extract alone [Plate 1f] and rats treated with 300 mg/kg of the extract [Plate 1f] showed the normal arrangement of the hepatocytes with no visible lesion. Liver of the positive control rats [Plate 1c] however showed diffuse necrotic vacuolations of the hepatocytes. Treatment with the extract however ameliorated the degenerations of the hepatocytes in a dose-dependent manner [Plates 1b and e].

DISCUSSION

Liver diseases are clinically diagnosed by elevation in the concentrations of hepatic enzymes in the serum of animals. Administration of CCl₄ in this study increased the serum concentrations of ALT, AST, ALP and GGT in all exposed rats compared to pre-administration concentrations. This correlates with findings of previous studies by Sharma [18] and Asha [24] who reported that CCl₄ intoxication raised the serum level of the liver enzymes by releasing these enzymes into the blood stream. The increase in enzyme levels might be due to leakage of these enzymes into the bloodstream as a result of CCl₄-induced tissue oxidative damage caused by free radicals being generated. Hepatotoxicity of CCl₄ have been reported to depend on the cleavage of the carbon-chlorine bond to generate a trichloromethyl free radical (CCl₃), and this free radical reacts rapidly with oxygen to form a trichloromethyl peroxy radical (CCl₃O₂) thereby generating oxidative stress in the hepatocytes [25]. Oxidative stress thus generated, causes lipid peroxidation in liver tissues and consequently necrosis of the liver cells with increased permeability of the plasma membrane leading to enzyme leakage into the blood stream [17,26,27]. The diffuse necrotic vacuolations of the hepatocytes observed in the liver of the positive control rats also attests to this postulation.

Table 4: RBC indices of CCl₄ induced rats treated with methanolic leaf extract of *F. exasperata*

| Group | PCV (%) | Hb (g/dl) | RBC (10 ⁶ μL) | Platelets (×10 ³ μl) | MCHC (g/dl) | MCV (femtoliter) | MCH (pg) |
|-------|--------------------------|--------------------------|--------------------------|---------------------------------|-------------|------------------|----------|
| A | 46.80±1.87 ^{ab} | 15.10±0.45 ^b | 7.80±0.35 ^{ab} | 67.8±7.69 ^b | 0.32 | 0.59 | 0.19 |
| B | 46.50±1.55 ^{ab} | 15.00±0.38 ^b | 7.90±0.31 ^b | 70.5±8.18 ^c | 0.32 | 0.59 | 0.19 |
| C | 45.30±1.37 ^{ab} | 14.20±0.75 ^{ab} | 7.20±0.15 ^a | 65.5±6.26 ^b | 0.32 | 0.61 | 0.19 |
| D | 47.00±3.00 ^b | 15.50±1.05 ^b | 8.00±0.71 ^{bc} | 75.7±3.04 ^c | 0.32 | 0.58 | 0.18 |
| E | 32.80±1.37 ^a | 10.70±0.71 ^a | 6.10±0.17 ^a | 58.4±6.42 ^a | 0.32 | 0.60 | 0.19 |
| F | 47.00±1.08 ^b | 15.80±0.17 ^b | 7.80±0.28 ^{ab} | 77.8±9.73 ^d | 0.32 | 0.60 | 0.20 |

Values are mean±SE, n≤5. Values within a column having different superscripts are significantly different at P<0.05. RBC: Red blood cell, PCV: Packed cell volume, Hb: Hemoglobin, MCHC: Mean cell hemoglobin concentration, MCV: Mean cell volume, MCH: Mean cell hemoglobin, SE: Standard error, *F. exasperata*: *Ficus exasperata*, CCl₄: Carbon tetrachloride, Group A: Control, Group B: CCl₄ injected treated with 100 mg/kg of the extract, Group C: CCl₄ injected treated with 200 mg/kg of the extract, Group D: CCl₄ injected treated with 300 mg/kg of the extract, Group E: Group injected with CCl₄ only, Group F: Group treated with 200 mg/kg of the extract only

Table 5: WBC and differentials of CCl₄ induced rats treated with methanolic leaf extract of *F. exasperata*

| Groups | WBC (×10 ³ cm ³) | Lymphocyte (×10 ³ /μl) | Neutrophils (×10 ³ /μl) | Monocytes (×10 ³ /μl) | Eosinophils (×10 ³ /μl) |
|--------|---|-----------------------------------|------------------------------------|----------------------------------|------------------------------------|
| A | 3.30±1.9 ^a | 75.30±2.70 ^a | 14.50±1.70 ^a | 1.50±0.30 ^a | 2.00±0.00 ^a |
| B | 3.50±1.1 ^a | 78.80±1.40 ^b | 17.30±1.10 ^b | 2.00±0.40 ^{ab} | 2.00±0.40 ^a |
| C | 4.10±1.9 ^b | 81.80±2.60 ^c | 16.50±3.90 ^{ab} | 3.30±0.60 ^b | 2.00±0.40 ^a |
| D | 4.80±1.5 ^c | 79.00±9.00 ^b | 17.00±7.00 ^b | 2.00±1.00 ^{ab} | 2.00±0.20 ^a |
| E | 5.70±1.8 ^d | 84.00±1.90 ^d | 17.30±3.00 ^b | 3.00±0.40 ^b | 2.50±0.50 ^a |
| F | 4.40±1.3 ^b | 78.30±4.00 ^b | 15.00±2.50 ^a | 1.75±0.50 ^{ab} | 1.50±0.50 ^a |

Values are mean±SE, n≤5. Values within a column having different superscripts are significantly different at P<0.05. SE: Standard error, WBC: White blood cell, *F. exasperata*: *Ficus exasperata*, CCl₄: Carbon tetrachloride, Group A: Control, Group B: CCl₄ injected treated with 100 mg/kg of the extract, Group C: CCl₄ injected treated with 200 mg/kg of the extract, Group D: CCl₄ injected treated with 300 mg/kg of the extract, Group E: Group injected with CCl₄ only, Group F: Group treated with 200 mg/kg of the extract only

Table 6: Effects of treatment with methanolic leaf extract of *F. exasperata* on antioxidant enzymes in CCl₄-induced rats

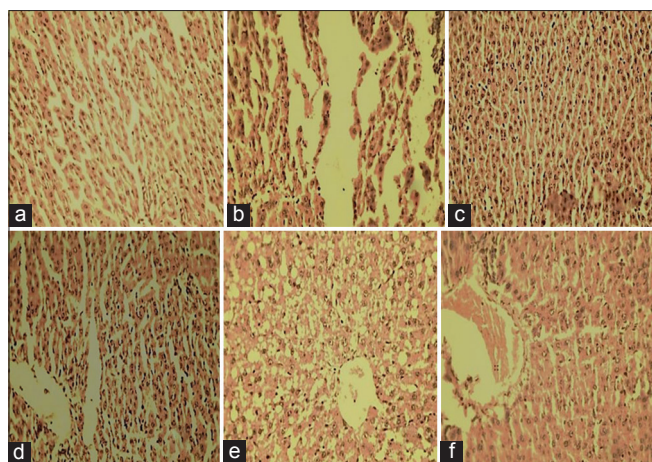
| Groups | Catalase (unit/ml) | Peroxidase (unit/ml) | SOD (unit/ml) | TPP (μmol trolox eqiuv/L) | TAP (μmol H ₂ O ₂ /L) | OSI (%) |
|--------|------------------------|------------------------|------------------------|---------------------------|---|-------------------------|
| A | 2.50±1.1 ^a | 2.20±1.1 ^a | 3.10±1.1 ^a | 13.00±3.4 ^b | 21.00±5.2 ^b | 5.40±2.23 ^a |
| B | 3.80±1.9 ^{ab} | 3.40±1.5 ^{ab} | 3.30±1.2 ^a | 13.50±2.6 ^a | 18.60±2.7 ^{ab} | 7.40±2.54 ^b |
| C | 3.10±1.2 ^{ab} | 2.40±1.6 ^{ab} | 3.60±1.7 ^{ab} | 13.20±4.9 ^a | 19.50±2.2 ^{ab} | 7.70±1.73 ^b |
| D | 3.90±1.2 ^b | 3.20±1.6 ^{ab} | 3.70±1.3 ^{ab} | 13.20±4.2 ^a | 23.60±7.4 ^b | 7.40±2.35 ^b |
| E | 5.70±1.1 ^c | 4.30±1.6 ^c | 6.40±1.5 ^b | 19.30±7.1 ^b | 11.50±5.8 ^a | 11.20±5.24 ^c |
| F | 2.60±1.7 ^a | 3.70±1.8 ^{ab} | 3.20±1.7 ^a | 13.20±9.6 ^a | 24.00±3.2 ^c | 5.70±2.56 ^a |

Values are mean±SE, n≤5. Values within a column having different superscripts are significantly different at P<0.05. SE: Standard error, *F. exasperata*: *Ficus exasperata*, CCl₄: Carbon tetrachloride, SOD: Superoxide dismutase, TAP: Total antioxidant potential, TPP: Total plasma peroxidase, OSI: Oxidative stress index, Group A: Control, Group B: CCl₄ injected treated with 100 mg/kg of the extract, Group C: CCl₄ injected treated with 200 mg/kg of the extract, Group D: CCl₄ injected treated with 300 mg/kg of the extract, Group E: Group injected with CCl₄ only, Group F: Group treated with 200 mg/kg of the extract only

Treatment with methanol leaf extract of *F. exasperata* herein attenuated the hepatotoxicity induced by CCl₄ as evidenced by marked decrease in plasma ALT, AST, ALP and GGT concentrations in treated rats. Although the principle responsible for this effect was not elucidated in this study, it may however be due to the antioxidant properties of the plant extract. Several reports have suggested diverse mechanisms by plants to ameliorate the hepatotoxic effects of CCl₄ such include antioxidant activities, inhibition of CYP2E1 [28] and activation of nuclear factor-kappa B, and inhibition of inflammatory cytokines [29]. The antioxidant component of the extract used in this study might be responsible for scavenging on the active CCl₃^{*} and CCl₃OO^{*} radicals generated thereby preventing further hepatic damage and reversing hepatic necrosis caused by CCl₄. Our findings showed that leaf extract of *F. exasperata* is rich in Vitamin C and other free radical scavenging minerals such as zinc and magnesium. Vitamin C has been particularly known to stimulate the immune function, inhibit nitrosamine

formation, and block the metabolic activation of carcinogens and most importantly, protects against and prevents oxidative stress [30]. The mild necrotic degenerations observed in the liver of rats treated with the extract compared to the untreated group also confirm the ameliorative activities of the extract.

Administration of CCl₄ in our study caused microcytic hypochromic anemia as evidenced by decrease in the levels of erythrocyte number, hemoglobin concentration and hematocrit values as well as marked leukocytosis in the positive control rats. Previous authors have reported that administration of CCl₄ caused a generalized reduction in cellular elements (pancytopenia; thrombocytopenia, and lymphopenia) and increase in leucocyte counts in the blood of injected rats [31,32]. It has been explained that this reduction in the formed elements in the blood might be stress induced due to the generation of highly reactive CCl₃^{*} and CCl₃OO^{*} radicals which induce oxidative stress in the blood cells [32,33].



Plates 1: (a) Liver of normal control rats showing no visible lesion. (b) Liver of rat treated with 200 mg/kg of extract showing no visible lesion. (c) Liver of carbon tetrachloride (CCl₄) injected rats showing marked diffused vacuolations of the hepatocytes. (d) Liver of CCl₄ injected rats treated with 100 mg/kg of the extract showing mild vacuolation of the hepatocytes. (e) Liver of CCl₄ injected rats treated with 200 mg/kg of the extract showing vacuolations of the hepatocytes. (f) Liver of CCl₄ injected rat treated with 300 mg/kg of the extract showing no visible lesion

Treatment with various doses of the extract of *F. exasperata* increased the erythrocyte indices compared to the untreated rats, which is an attestation to the hematopoietic potentials of the plant. This is a confirmation of our previous observation [34] that treatment with aqueous extract of *F. exasperata* improved the hematocrit values and reversed acute anemia in treated diabetic rats. The reason for this may be due to the presence of hematopoietic vitamins that are abundant in the plant extract. Folate and vitamin B12 are important for DNA synthesis, cell division and particularly the formation of new erythrocytes in the bone marrow, while vitamins B2 and C are responsible for hematological responses to and absorption of dietary iron, respectively.

WBC plays an important role in the immune system of the living organism. Values of total WBC and lymphocytes, neutrophils, monocytes and eosinophils counts in the treated groups were higher compared to the control rats. The increase in WBC and lymphocytes observed in the study may be attributed to immune response of the animals following treatment. The previous study by Saba *et al.* [32] also reported increases in lymphocyte and neutrophil counts in CCl₄-induced rats treated with aqueous leaf extract of *Cnidioscolus aconitifolius*.

Living organisms possess various enzymatic and nonenzymatic antioxidant systems which function to protect from damages caused by oxidative stress. These systems perform the functions of scavenging and detoxifying free radicals, blocking their production and sequestering metals which may serve as sources of free radicals [35]. Administration of CCl₄ increased the serum activity of the enzymatic antioxidant enzymes (catalase, peroxidase, and SOD) assayed in our study. This increase might be due to the mobilization of the antioxidant enzymes in the rats to scavenge and detoxify the CCl₃^{*} and CCl₃OO^{*} radicals produced as a result of the reduction reaction of CCl₄.

The lower concentrations of antioxidant enzymes in rats treated with the extract are an indication of the free radical interception and repair activities of the antioxidant profile in our plant extract. Devasagayam *et al.* [36] posited that antioxidants act at different stages of prevention, interception, and repair. Preventive antioxidants attempt to stop the formation of reactive oxygen species. These include SOD and catalase [37,38]. Interception of free radicals is mainly by radical scavenging by various antioxidants such as vitamins C and E, glutathione, carotenoids, and flavonoids. At the repair and reconstitution level, mainly repair enzymes as vitamin C are involved such. Many of these compounds are found to be abundant in extract of *F. exasperata* and might have been responsible for neutralizing the free radicals consequently leading to the reduction in the serum concentrations of assayed antioxidant enzymes in our study.

Our findings also showed that injection with CCl₄ caused diffused vacuolations of the hepatocytes. Studies have demonstrated cause-to-effect links between exposure to toxicants and the development of hepatic lesions [39]. Treatment with methanolic leaf extract of *F. exasperata* ameliorated the degenerations of the hepatocytes, and this activity was found to be dose dependent. This and other results of this study have demonstrated that methanolic extract of *F. exasperata* ameliorated the various biomarkers of CCl₄-induced hepatopathy by enhancing the antioxidant systems.

The amelioration of hepatic damage caused by administration of CCl₄ by extract of *F. exasperata* could form the basis of the folklore medicinal use of the plant in the treatment of liver diseases. Our findings have therefore identified *F. exasperata* as a potent alternative treatment for liver disease. Further studies to isolate and characterize the components of the plant that are responsible for the ameliorative activities are therefore suggested.

REFERENCES

1. Dienstag JL, Isselbacher KJ. Toxic and drug-induced hepatitis. In: Fauci A, Braunwald E, Kasper D, editors. *Harrison's Principles of Internal Medicine*. 15th ed., Vol. 2. Ch. 296. New York: The McGraw-Hill Companies; 2001. p. 1737-42.
2. Athar M, Zakir HS, Hasan N. Drug metabolizing enzymes in the liver. In: Rana SV, Taketa K, editors. *Liver and Environmental Xenobiotics*. New Delhi: Narosa Publishing House; 1997. p. 4-16.
3. Kshirsagar A, Mohite R, Aggrawal AS, Suralkar U. Hepatoprotective medicinal plants of Ayurveda - A review. *Asian J Pharm Clin Res* 2011;4:1-8.
4. Kim HY, Kim JK, Choi JH, Jung JY, Oh WY, Kim DC, *et al.* Hepatoprotective effect of pinoreosinol on carbon tetrachloride-induced hepatic damage in mice. *J Pharmacol Sci* 2010; 112: 105-12.
5. Agency for Toxic Substances and Disease Registry (ATSDR). *Toxicological Profile for Carbon Tetrachloride*. Atlanta, GA: US Department of Health and Human Services, Public Health Service; 2005. p. 2-4.
6. Zhu W, Fung PC. The roles played by crucial free radicals like lipid free radicals, nitric oxide, and enzymes NOS and NADPH in CCl₄-induced acute liver injury of mice. *Free Radi Biol Med* 2000;29:870-80.
7. Lewis DF. Essential requirements for substrate binding affinity and selectivity toward human CYP2 family enzymes. *Arch Biochem Biophys* 2003;409:32-44.
8. Galli A, Schiestl RH. Effect of *Salmonella* assay negative and positive carcinogens on intrachromosomal recombination in S-phase arrested

- yeast cells. *Mutat Res* 1998;419:53-68.
9. Brennan RJ, Schiestl RH. Chloroform and carbon tetrachloride induce intrachromosomal recombination and oxidative free radicals in *Saccharomyces cerevisiae*. *Mutat Res* 1998;397:271-8.
 10. Cowman MM. Plant products as antimicrobial agents. *Clin Microbiol Rev* 1999;12:564-82.
 11. Ijeh II, Ukweni AI. Acute effect of administration of ethanol extracts of *F. exasperata* vahl on kidney function in albino rats. *J Med Plant Res* 2007;1:27-9.
 12. Ndukwe KC, Okeke IN, Lamikanra A, Adesina SK, Aboderin O. Antibacterial activity of aqueous extracts of selected chewing sticks. *J Contemp Dent Pract* 2005;6:86-94.
 13. Nimenibo-Uadia R. *Ficus exasperata*: Effects on diabetes mellitus in an experimental rat model. *Glob J Pure Appl Sci* 2003;9:529-32.
 14. Palombo EA. Phytochemicals from traditional medicinal plants used in the treatment of diarrhoea: Modes of action and effects on intestinal function. *Phytother Res* 2006;20:717-24.
 15. Acharya D, Shrivastava A. *Indigenous Herbal Medicines: Tribal Formulations and Traditional Herbal Practices*. Jaipur, India: Aavishkar Publishers Tributor; 2008. p. 440.
 16. Adebayo EA, Ishola OR, Taiwo OS, Majolagbe ON, Adekeye BT. Evaluations of the methanol extract of *Ficus exasperata* stem bark, leaf and root for phytochemical analysis and antimicrobial activities. *Afr J Plant Sci* 2009;3:283-7.
 17. Das P, Panda P, Pani S, Sethi R. Hepatoprotective activity of plant *Argemone Mexicana* (Linn). Against carbon tetrachloride (CCl₄) induced hepatotoxicity in rats. *Int J Pharm Res Dev Online* 2008;8:1-20.
 18. Sharma HD. Hepatoprotective potential of *Aloe barbadensis* Mill. Against carbon tetrachloride induced hepatotoxicity. *Int J Res Pharm Biomed Sci* 2012;3:1119-24.
 19. Tahir M, Inam-ul-Haq A, Naseem N, Latif M, Naveed A, Hassan M, et al. Hepatoprotective potential of '*Rheum emodi* wall' on carbon tetrachloride-induced hepatic damage. *Ann Pak Inst Med Sci* 2008;(3):152-5.
 20. Venukumar MR, Latha MS. Hepatoprotective effect of the methanolic extract of *Curculigo orchiooides* in CCl₄-treated male rats. *Indian J Pharmacol* 2002;34:269-75.
 21. Trease GE, Evans WC. *Pharmacognosy*. 15th ed. Philadelphia, PA: Lea and Febiger Press; 1989. p. 882.
 22. AOAC (Association of Official Analytical Chemists). *Method of Analysis*. Washington, DC: AOAC; 2005. p. 12-15.
 23. Tietz N, Prude WE, Sirgard-Anderson O. In: Burtis CA, Ashwood ER, editors. *Tietz Textbook of Clinical Chemistry*. London: WB Saunders Company; 1994. p. 1354-74.
 24. Asha VV. Preliminary studies on the hepatoprotective activity of *Mamordica Subangulata* and *Naragamia alata*. *Indian J Pharmacol* 2001;33:276-9.
 25. Donfack J, Nico F, Ngameni B, Pascal A, Chuisseu D, Finzi P, et al. *In vitro* hepatoprotective and antioxidant activities of diprenylated isoflavonoids from *Erythrina senegalensis* (Fabaceae). *Asian J Tradit Med* 2008;3:172-8.
 26. Rana SV, Singh R, Verma S. Protective effects of few antioxidants on liver function in rats treated with cadmium and mercury. *Indian J Exp Biol* 1996;34:177-9.
 27. Sharma MK, Kumar M, Kumar A. *Ocimum sanctum* aqueous leaf extract provides protection against mercury induced toxicity in Swiss albino mice. *Indian J Exp Biol* 2002;40:1079-82.
 28. Jeong HG, You HJ, Park SJ, Moon AR, Chung YC, Kang SK, et al. Hepatoprotective effects of 18beta-glycyrrhetic acid on carbon tetrachloride-induced liver injury: Inhibition of cytochrome P450 2E1 expression. *Pharmacol Res* 2002;46:221-7.
 29. Yoh T, Nakashima T, Sumida Y, Kakisaka Y, Nakajima Y, Ishikawa H, et al. Effects of glycyrrhizin on glucocorticoid signaling pathway in hepatocytes. *Dig Dis Sci* 2002;47:1775-81.
 30. Lee KW, Lee HJ, Surh YJ, Lee CY. Vitamin C and cancer chemoprevention: Reappraisal. *Am J Clin Nutr* 2003;78:1074-8.
 31. Moritz RP, Pankow D. Effect of carbon tetrachloride and chloroform on hematologic parameters in rats. *Folia Haematol Int Mag Klin Morphol Blutforsch* 1989;116:283-7.
 32. Saba AB, Oyagbemi AA, Azeez OI. Amelioration of carbon tetrachloride-induced hepatotoxicity and haemotoxicity by aqueous leaf extract of *Cnidioscolus aconitifolius* in rats. *Niger J Physiol Sci* 2010;25:139-47.
 33. Swenson MJ. Physiological properties and cellular and chemical constituent of blood. In: *Dukes' Physiology of Domestic Animals*. Ithaca, London: Comstock Publishing Associates; 1993. p. 29-32.
 34. Adeyi AO, Idowu AB, Mafiana CF, Oluwalana SA, Ajayi OL. Effects of aqueous leaf extract of *Ficus exasperata* on pathophysiology and histopathology of alloxan-induced diabetic albino rats. *J Med Plants Res* 2012;6:5730-6.
 35. Halliwell B, Gutteridge JM. *Free Radicals in Biology and Medicine*. 4th ed. Oxford: Clarendon Press; 2007. p. 13-20.
 36. Devasagayam TP, Tilak JC, Boloor KK, Sane KS, Ghaskadbi SS, Lele RD. Free radicals and antioxidants in human health: Current status and future prospects. *J Assoc Physicians India* 2004;52:794-804.
 37. Sies H, editor. *Antioxidants in Disease Mechanisms and Therapy*. New York: Academic Press; 1996. p. 35-56.
 38. Cadenas E, Packer L, editors. *Hand Book of Antioxidants*. New York: Plenum Publishers; 1996. p. 21-43.
 39. Rabbito IS, Alves Costa JR, Silva de Assis HC, Pelletier EE, Akaishi FM, Anjos A, et al. Effects of dietary Pb(II) and tributyltin on neotropical fish, *Hoplias malabaricus*: Histopathological and biochemical findings. *Ecotoxicol Environ Saf* 2005;60:147-56.

© EJManager. This is an open access article licensed under the terms of the Creative Commons Attribution Non-Commercial License (<http://creativecommons.org/licenses/by-nc/3.0/>) which permits unrestricted, noncommercial use, distribution and reproduction in any medium, provided the work is properly cited.

Source of Support: Nil, Conflict of Interest: None declared.