



Naja nigricollis venom altered reproductive and neurological functions via modulation of pro-inflammatory cytokines and oxidative damage in male rats

Babafemi Siji Ajisebiola^{a,*}, Olukemi Blessing Adeniji^a, Adewale Segun James^b, Babajide O. Ajayi^c, Akindele Oluwatosin Adeyi^{d,**}

^a Department of Zoology, Osun State University, Osogbo, Nigeria

^b Department of Chemical Sciences (Biochemistry Program), Augustine University, Lagos, Nigeria

^c Onco-preventives and Systems Oncology Research Laboratory, Biochemistry Unit, Department of Chemical Sciences, Ajayi Crowther University, Oyo, Nigeria

^d Animal Physiology Unit, Department of Zoology, University of Ibadan, Ibadan, Nigeria

ARTICLE INFO

Keywords:

Naja nigricollis
Reproductive toxicity
Snakebite
Neurotoxicity
Envenoming

ABSTRACT

Reproductive and neurological anomalies are often characterized by malfunctioning of reproductive and nervous organs sometimes attributed to systemic toxins. However, limited information is available on the impact of snake venom toxins on male reproductive and nervous system. This study investigated the toxicological effects of *Naja nigricollis* venom on male reproductive and neural functions in rat model. Twenty male Wistar rats weighing between 195 and 230 g were divided randomly into two groups of ten rats each. Group 1 served as normal control while rats in group 2 were envenomed with a single intraperitoneal injection of 0.25 mg/kg⁻¹ (LD_{12.5}) of *N. nigricollis* venom on first and twenty fifth day within the period of fifty days experiment. The venom significantly decreased sperm counts, motile cells and volume combined with increased sperm abnormalities. The venom induced hormonal imbalances in the envenomed group as levels of testosterone, luteinizing and follicle stimulating hormones depreciated compared to the control. Oxidative stress biomarkers: malondialdehyde significantly increased parallels with depletion of glutathione level and catalase activities in testis, epididymis and brain of envenomed rats. Furthermore, *N. nigricollis* venom up-regulated tumor necrosis factor-alpha (TNF- α) and interleukin1-beta (IL-1 β) production in testis, epididymis and brain of envenomed rats compared to the control. Also, various histological alterations were noticed in tissues of testis, epididymis and brain of envenomed rats. Findings indicated that *N. nigricollis* venom is capable of inducing reproductive and neurological dysfunction in envenomed victims.

1. Introduction

Venomous snakes are species that produces venom in their venom glands and these group of snakes have been classified into diverse families and sub families [1]. However, report abounds that fatalities resulting from snake envenoming are largely due to bites from species that belongs to Viperidae (Vipers) and Elapidae (Elapids) families [1]. The predatory behaviours of vipers and elapids differs, the former typically ambush their prey by injecting an haemotoxic venom which contains mainly large proteins that majorly causes haemostatic disturbances, while the latter where cobras belongs are active predators with

venoms predominantly composed of neurotoxic and cytotoxic proteins and peptides that typically attacks the central nervous system [2].

Cobras are known to inflict multiple-organ failure after venom injection which often results to death in case of severe envenomation [3]. Symptoms that manifests after envenoming by cobra are local pain, severe swelling, blistering, necrosis and other non-specific effects [4]. Biochemically, cobra venoms are mixtures of proteins, peptides, enzymes, cytotoxins, coagulants and neurotoxins exhibiting toxic actions in living systems [5]. The neurotoxins in cobra venom blocks the transmission of nerve impulses to the muscles consequently affecting the nervous system, heart and lungs thereby leading to organ

* Corresponding author.

** Corresponding author.

E-mail addresses: dbabslinks@yahoo.com (B.S. Ajisebiola), delegenius@yahoo.com (A.O. Adeyi).

malfunctioning and ultimately death as a result of complete failure of respiratory function [6].

Naja nigricollis commonly called black-necked spitting cobra is a venomous snake species belonging to a widely distributed snake family known as the Elapidae [7]. The specie is one of the most medically important elapids and their envenoming have resulted to quite a number of morbidity and mortality among rural dwellers in Nigeria [8]. Incidentally, *N. nigricollis* is believed to be the most urbanized specie, as many victims of their bites resides in urban areas in Africa [9].

The only treatment of snake envenoming is the use of serum anti-venom which are ineffective against local tissue damage and cannot reverse the damages to organ systems [10]. Also, most rural dwellers use traditional methods for snake bite treatment due to inaccessibility to antivenoms and some of these treatments may only ameliorates and not effectively and completely halt further actions of venom toxins on vital organs of the body. Furthermore, most antivenoms do not effectively neutralize snake venom due to toxins variations as they are produced using the snake species of a location and imported to a different country for use. As a result of these shortcomings, snake envenomed victims may encounter other physiological damages to their organ system functions due to the venom toxins which may not be fatal. Consequently, there is paramount need to investigate the effect of venom toxins at tissue level of important reproductive and nervous organs of human body after envenoming.

Investigators of toxicology had since launch researches on numerous effects of snake venoms in cells, tissues and organ systems of animals with outstanding reports [11–13] but limited information is available on their reproductive and neural toxicology. Although, snake venom toxins from *Daboia russelli* have been documented to induced atrophy in testis of mice [14] while *Crotalus durissus* ssp. (rattlesnake) venom could cause an increase in sperm morphology abnormality [15]. Also, toxins present in *Bothrops jararaca* have been reported to inhibit spermatozo production [16]. Despite the available information, the impact of *N. nigricollis* envenoming on male reproductive and neural functions in biological system remain unreported. Whereas, diverse pathophysiology attributed to venom toxins of *N. nigricollis* venom have been studied and information on their toxicities in different biological systems are available [1,17,18]. Hence, the present study was aimed to unravel the potential damage caused by *N. nigricollis* envenoming on male reproductive and nervous organs in male albino rats.

2. Materials and methods

2.1. Chemicals and kits

The rats enzyme-Linked Immunosorbent Assay (ELISA) Kits for Testosterone, FSH and LH assays were procured from Bio-Inteco Diagnostic Ltd., Ken House, London, UK while enzyme-linked immunosorbent assay (ELISA) kits manufactured by PeptoTech, Inc. London, UK were used for TNF- α and IL-1 β assays. Other reagents and chemicals were of good grade and purchased from Sigma-Aldrich, Inc, USA.

2.2. Venom collection

A lyophilized venom of *N. nigricollis* was obtained from herpetarium of the Department of Veterinary Physiology and Pharmacology, Amadu Bello University, Zaria, Nigeria. The venom sample was transported via a cooling container at maintained temperature of 4 °C to the Animal Physiology Laboratory, Department of Zoology, University of Ibadan, Nigeria. The lyophilized venom was stored at 4 °C until required.

2.3. Experimental animals

Male albino Wistar rats (weighing between 195 and 230 g; 14 weeks old; n = 10) were procured from the Animal House of the Department of Zoology, University of Ibadan, Ibadan, Nigeria. The animals were placed

in a transparent plastic cages on a 12 h light/dark cycle and allowed free access to standard pelleted rat chow and tap water *ad libitum*. The experimental protocol was conducted in accordance with the regulations of the local ethics committee in animal care and use in Research of the University of Ibadan, Nigeria. The animal experiment complied with the National Research Council's publication on guide for the care and use of laboratory animals [19].

2.3.1. Experimental groups

The rats were randomly distributed into two groups of ten rats (n = 10) each. Group 1 were injected with 0.2 ml of saline and served as normal control while group 2 were envenomed with 0.2 ml of *N. nigricollis* venom and served as the venom group.

2.3.2. Envenoming procedures

The lethal dose concentration (LD₅₀) of *N. nigricollis* venom based on our previous study was 1.0 mg [17]. In this current study, rats were envenomed with a single intraperitoneal injection of 0.25 mg/kg⁻¹ (LD_{12.5}) of *N. nigricollis* after the venom dose was reconstituted in 10 ml of normal saline. The animals were envenomed with 0.2 ml of the venom on Day 1 with a repeated dose on Day 25 of the experiment at 8:00 a.m. each day. All rats were observed for a period of 50 days post envenomation and mortalities were recorded. The exposure duration of 50 days was selected based on the completion of rat spermatogenesis [20]. Animals were monitored for clinical signs of toxicity including food and water consumption behavioral patterns and mortality.

2.3.3. Determination of body weight gain

The body weight of animals was measured before venom injection on day 1 and prior to day 50 before they were sacrificed as terminal weight. The body weight gain was calculated using the formula:

$$\text{Body weight gain} = \frac{\text{Terminal weight of rats} - \text{Initial weight of rats}}{\text{Initial weight of rats}} \times 100$$

2.3.4. Blood sample and organs collection

At post-envenomation, blood from the experimental rats was collected using heparinised capillary tubes into plain bottles through retro-orbital sinus punctuation and centrifuged at 380 g for 10 min to obtain serum for hormonal assays. Immediately after blood collection, the rats were sacrificed by cervical dislocation following the protocol of Rowett, [21]. The cauda epididymis was surgically removed and processed for sperm parameters analysis. The testes and brain were also removed and weighed. Parts of tissues of the epididymis, testes and brain were used for biochemical assays while the remaining parts were preserved in Bouin's fluid and 10% formalin respectively before been processed for histological analysis. The relative testes and brain weight were determined using the formula:

$$\text{Relative organ weight} = \frac{\text{Organ weight}}{\text{Terminal body weight}} \times 100$$

2.4. Determination of sperm parameters

2.4.1. Sperm counts

For sperm count, a 1:10 serial dilution of the sperm suspension was used with the aid of an improved Neubauer hemocytometer using the protocol of previously described [22]. After dilution, exactly 100 μ l of sperm suspension was loaded onto the hemocytometer to count the spermatozoa under a light microscope at a 400 \times magnification. Sperm count values were multiplied by the dilution factor and recorded as millions per milliliter (10⁶/ml). To evaluate the sperm volume, the epididymis was immersed in 5 mL normal saline in a measuring cylinder and the volume displaced was taken as the volume of the epididymis [23].

2.4.2. Sperm motility

The cauda epididymis was placed individually in a Petri dish and minced in normal saline (1 ml) to form the sperm suspension, and 10 μ l were placed in triplicate on microscopic slides and observed for motility under the light microscope at a magnification of $\times 400$. Sperm motility was assessed by classifying 200 spermatozoa into two categories, motile and immotile spermatozoa. Three sperm classes were categorised as motile spermatozoa: rapid progressive, slow progressive and non-progressive spermatozoa [24].

2.4.3. Sperm morphology

The assessment of sperm morphological abnormalities was carried out following the protocol of Wyrobek et al. [25]. 450 μ l of the sperm suspension was mixed with 50 μ l of 1% aqueous eosin Y for 10 min. The stained sperm suspension was used to make a thin smear on a pre-cleaned grease-free microscopic slide. Prepared slides were allowed to air dry and abnormalities were observed in 250 spermatozoa with four replicates in each rat at a magnification of $\times 1000$.

2.5. Hormonal assays

The levels of free sera sex hormones were measured for testosterone, luteinizing hormone (LH) and follicle stimulating hormone (FSH) using Bio-Inteco Enzyme-Linked Immunosorbent Assay (ELISA) Kit (Inteco Diagnostic, UK). The optical density was taken at 450 nm with a microplate reader.

2.6. Antioxidant parameters in testis, epididymis and brain tissues

Lipid peroxidation end product; malondialdehyde (MDA), was measured as thiobarbituric acid reactive substance (TBARS) as described [26]. Catalase activity (CAT) was measured as described [27], while levels of reduced glutathione (GSH) were assayed according to the method of Ellman [28].

2.7. Measurement of pro-inflammatory cytokines production in testis, epididymis and brain tissues

2.7.1. Tissue preparation

Frozen testis, epididymis and brain tissue samples were homogenized in a 1.5 mL RIPA buffer (25 mM TrisHCl, 150 mM NaCl, 1% NP-40, 1% sodium deoxycholate, 0.1% SDS pH = 7.6) supplemented with Protease inhibitors at 4 °C. The homogenate was incubated on ice for 30 min and then centrifuged at 10,000 \times g for 30 min at 4 °C. Following centrifugation, the supernatants were transferred to labelled Eppendorf and stored at -80 °C for cytokine measurement.

2.7.2. Measurement of tumor necrosis factor-alpha (TNF- α) and Interleukin1-Beta (IL-1 β) production

Quantitative measurement of the level of cytokines was performed using Mini Enzyme Linked Immunosorbent Assay (ELISA) Development Kits (Peprotech). Well plates were set up according to the manufacturer's instructions and read using an ELISA plate reader at 405 nm with 650 nm as the correction wavelength. Concentrations (pg/mL) of testis, epididymis and brain TNF- α and IL-1 β were estimated [29].

2.8. Histopathological evaluation

The testis, epididymis and brain tissues from the control and envenomed groups were examined for histological studies using conventional techniques of paraffin-wax sectioning and hematoxylin-eosin staining [30].

2.9. Data analysis

Data were presented as mean \pm Standard Error of mean (SEM) and

analyzed using T-Test to compare the significant ($P < 0.05$) differences between the experimental and control group. Independent Sample test was used for comparison. All statistical analyses were done using GraphPad Prism version 7.0.

3. Results

3.1. Clinical signs of toxicity

Rats in the envenomed group showed some clinical signs of toxicity including: dizziness, low appetite for food with increase in water consumption and mortality. Mortalities were not observed in the normal control rats while only one death occurred on 20th day of the experiment in the envenomed group (Table 1). The body weight gain of normal control rats was significantly ($P < 0.05$) higher compared to the envenomed rats. Testicular and brain weights of envenomed rats significantly ($P < 0.05$) decreased compared to the control rats while the same trend was observed in the organo-somatic index of the experimental rats (Fig. 1).

3.1.1. The effects of *N. nigricollis* venom on sperm parameters

N. nigricollis envenomation induced a significant decrease ($p < 0.05$) in the percentage of motile spermatozoa compared to the control rats. Consequently, a significant increase ($p < 0.05$) in immotile spermatozoa was noticed in the envenomed rats compared to the control (Table 3). Sperm volume and count was significantly ($p < 0.05$) decreased in envenomed rats compared to the control (Table 2).

3.1.2. The effects of *N. nigricollis* venom on sperm morphology of envenomed rats

The percentage of sperm abnormalities showed a significant ($p < 0.05$) increase in the envenomed rats compared to the control. However, the sperm abnormalities as revealed in control rats have no unique abnormal spermatozoa compared to the sperm abnormalities noticed in envenomed rats (Table 3). High sperm abnormalities caused by the venom as noticed were short hook, banana shape and amorphous head respectively while unique sperm abnormalities observed were double tail, double head and Long and sickled hook (Table 3).

3.2. The effects of *N. nigricollis* venom on reproductive hormones

The serum concentration of luteinizing hormone (LH) and testosterone (TEST) of envenomed rats significantly ($P < 0.05$) reduced compared to the control. However, follicle stimulating hormones (FSH) of normal control was statistically ($P < 0.05$) not different compared to envenomed group however, there was a marked reduction in FSH levels of envenomed group compared to control (Table 4).

3.3. Effects of *N. nigricollis* venom on catalase enzyme activities of testis, epididymis and brain tissues

The activities of catalase (CAT) in epididymis and brain tissues of the control were significantly ($P < 0.05$) not different compared to envenomed rats, however, a marked decrease in CAT activities was observed in envenomed rats compared to the control. Whereas, the venom

Table 1
Mortality observed in envenomed group during experimental period Number of Death.

Groups	Envenomation	Day 1	Day 20	Day 50	Mortality (%)
Control	-	-	-	-	0.00
Envenomed	-	-	1	-	10.00

Number of rats per group (n = 10).

Data are represented as mean \pm SE (n = 5). Values in the same column with different superscript are considered significant ($p < 0.05$).

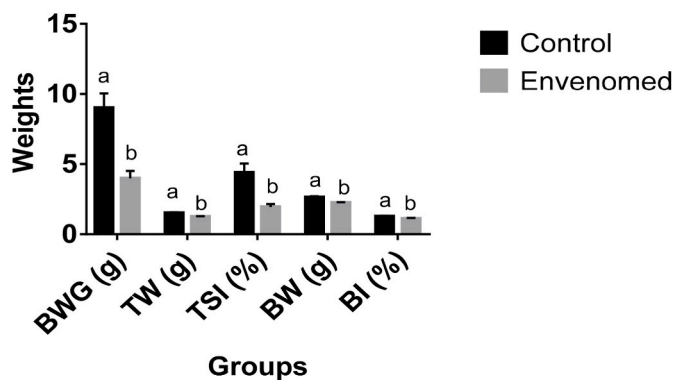


Fig. 1. The body weight gain (BWG), Testicular weight (TW), Testiculosomatic index (TSI), Brain weight (BW) and Brain index (BI) of experimental rats.

Table 2
Effects of *N. nigricollis* venom on sperm parameters of envenomed rats.

Groups	Sperm Motility (%)	Sperm Volume (mL)	Sperm Count (10 ⁶ /mL)
Control	79.06 ± 1.55 ^a	20.94 ± 1.06 ^a	8.28 ± 1.09 ^a
Envenomed	10.55 ± 1.00 ^b	89.45 ± 2.06 ^b	4.59 ± 0.72 ^b

Data are expressed as MEAN ± S.E. (n = 5). Values in the same column with different superscript are considered significant (p < 0.05).

Table 3
Sperm morphological abnormality counts in rats envenomed with *N. nigricollis* venom.

Sperm Parameters	Control	Envenomed
Amorphous head (AM)	5.67 ± 1.45 ^a	57.85 ± 0.75 ^b
Banana shape (BS)	6.42 ± 1.32 ^a	45.23 ± 1.41 ^b
Double tails (DT)	00.00 ± 0.00 ^a	29.10 ± 1.14 ^a
Folded Sperm (FS)	1.24 ± 0.54 ^a	43.90 ± 1.02 ^b
Knobbed head (KH)	2.67 ± 0.63 ^a	34.37 ± 1.00 ^b
Long and sickled hook (LSH)	00.00 ± 0.00 ^a	27.52 ± 0.50 ^a
Double head (DH)	00.00 ± 0.00 ^a	27.25 ± 0.70 ^a
Short hook (SH)	7.02 ± 1.14 ^a	47.32 ± 3.67 ^b
Wrong tail attachment (WTA)	3.62 ± 0.70 ^a	36.53 ± 1.67 ^b
Pin head (PH)	4.18 ± 0.87 ^a	28.42 ± 1.14 ^a
No hook (NH)	5.56 ± 1.00 ^a	54.22 ± 1.30 ^b
Wrong-angled hook (WAH)	3.37 ± 0.48 ^a	30.97 ± 1.16 ^b
Total abnormal cells	39.75 ± 2.30 ^a	462.68 ± 4.60 ^b
Percentage abnormalities	3.98 ± 1.33 ^a	46.27 ± 1.41 ^b

Data are represented as mean ± SE (n = 5). Mean ± S.E in the same column having similar superscript are not significantly different at P < 0.05. Mean ± S.E are fractions of the 1000 sperm cells assessed.

Table 4
Levels of the reproductive hormones in the blood of the rats envenomed with *N. nigricollis* venom.

Groups	LH (ng/ml)	FSH (ng/ml)	TEST (ng/ml)
Control	50.33 ± 2.02 ^a	455.33 ± 49.46 ^a	2.33 ± 0.10 ^a
Envenomed	42.33 ± 0.88 ^b	336.33 ± 54.81 ^a	1.25 ± 0.20 ^b

Data are expressed as MEAN ± S.E. (n = 5). Values in the same column with different superscript are considered significant (p < 0.05).

LH: Luteinizing Hormone, FSH: Follicle Stimulating Hormone, TEST: Testosterone Hormone.

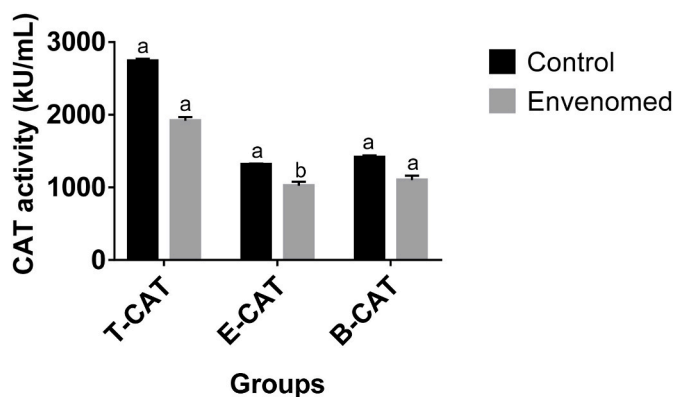


Fig. 2. Effects of *N. nigricollis* venom on catalase enzyme activities of the testis, epididymis, and brain of envenomed rats. Data are expressed as MEAN ± S.E. (n = 5). Values with the same superscript are considered not significant (p < 0.05). T-CAT: Testis Catalase, E-CAT: Epididymis Catalase, B-CAT: Brain Catalase.

significantly (P < 0.05) decreased CAT activities in the testis of envenomed rats compared to the control (Fig. 2).

3.3.1. The effects of *N. nigricollis* venom on glutathione enzyme levels in testis, epididymis and brain tissues

The glutathione (GSH) level was more prominent in testis and epididymis of control whereas levels of GSH was depleted in the envenomed rats although the values were statistically (P < 0.05) not different. On the other hand, the venom caused a significantly (P < 0.05) reduction in GSH levels of brain tissues in envenomed rats compared to control (Fig. 3).

3.3.2. Effects of *N. nigricollis* venom on malondialdehyde levels of the testis, epididymis and brain tissues

The venom significantly (P < 0.05) increased the malondialdehyde (MDA) levels of epididymis and testis tissues of envenomed rats compared to control. The MDA levels of brain tissues in envenomed group was statistically (P < 0.05) not different from control, however, MDA levels was more evident in brain tissues of envenomed group compared to the control (Fig. 4).

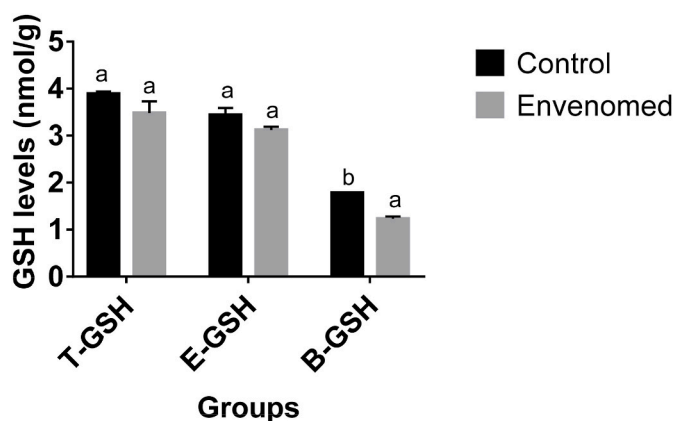


Fig. 3. Effects of *N. nigricollis* venom on glutathione enzyme levels of the testis, epididymis, and brain of envenomed rats. Data are expressed as MEAN ± S.E. (n = 5). Values with the same superscript are considered not significant (p < 0.05). T-GSH: Testis Glutathione, E-GSH: Epididymis Glutathione, B-GSH: Brain Glutathione.

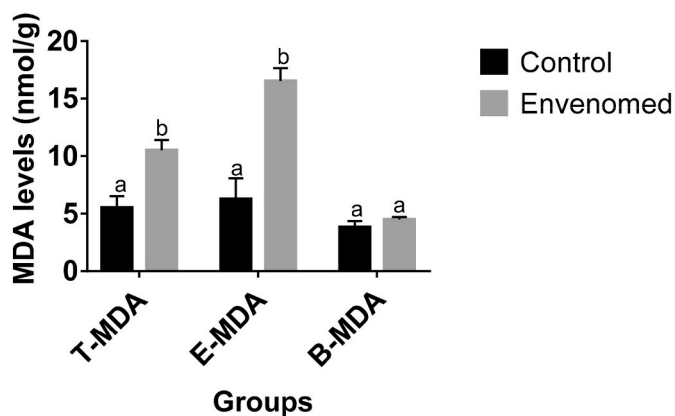


Fig. 4. Effects of *N. nigricollis* venom on malondialdehyde levels of the testis, epididymis and brain of envenomed rats. Data are expressed as MEAN \pm S.E, (n = 5). Values with the same superscript are considered not significant ($p < 0.05$). T-MDA: Testis Malondialdehyde, E-MDA: Epididymis Malondialdehyde, B-MDA: Brain Malondialdehyde.

3.4. Effects of *N. nigricollis* venom on Interleukin1-Beta (IL-1 β) production in envenomed rats

The interleukin1-Beta (IL-1 β) responses attributed to the venom action in epididymis and brain tissues was significantly ($P < 0.05$) not different to control, although the responses was more intense in envenomed group compared to control. Whereas, IL-1 β production in the testis tissues of the envenomed rats significantly ($P < 0.05$) increase compared to the control (Fig. 5).

3.4.1. Effects of *N. nigricollis* venom on tumor necrosis factor-alpha (TNF- α) production in envenomed rats

Production of tumor necrosis factor-alpha (TNF- α) as a result of venom injection significantly ($P < 0.05$) increased in the epididymis and brain tissues compared the control however, response to TNF- α in testis tissues of envenomed rats was statistically ($P < 0.05$) not different to the control although, TNF- α production was higher in the envenomed rats (Fig. 6).

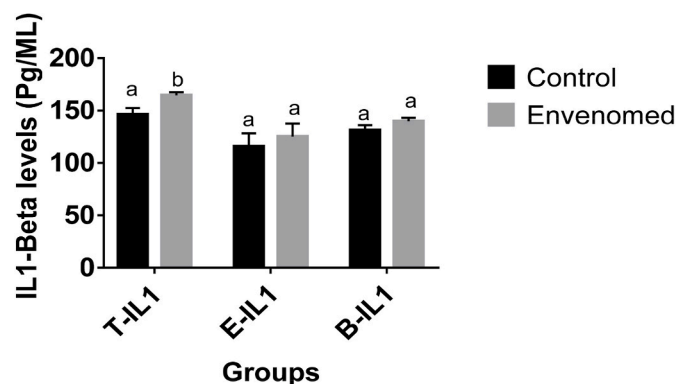


Fig. 5. Effects of *N. nigricollis* venom on Interleukin1-Beta (IL-1 β) production in the epididymis, testis and brain tissues of envenomed rats. Data are expressed as MEAN \pm S.E, (n = 5). Values with the same superscript are considered not significant ($p < 0.05$). T-IL1: Testis Interleukin1-Beta, E-IL1: Epididymis Interleukin1-Beta, B-IL1: Brain Interleukin1-Beta.

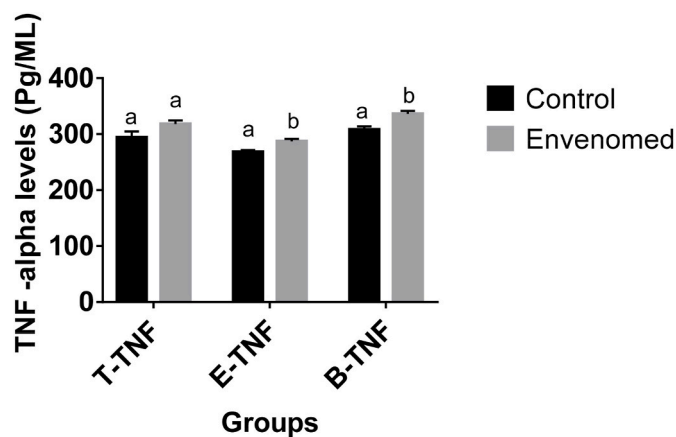


Fig. 6. Effects of *N. nigricollis* venom on tumor necrosis factor-alpha (TNF- α) production in the epididymis, testis and brain tissues of envenomed rats T-TNF: Testis Tumor necrosis factor-alpha, E-TNF: Epididymis Tumor necrosis factor-alpha, B-TNF: Brain Tumor necrosis factor-alpha. Data are expressed as MEAN \pm S.E, (n = 5). Values with the same superscript are considered not significant ($p < 0.05$).

3.5. Histopathological assessment of the testis, epididymis and brain tissues

The examinations of the testis, epididymis and brain revealed various histological defects. The testis of control rats showed no observable lesion as several uniformly sized, closely packed seminiferous tubules with regular outlines were observed and contained countless spermatogenic cells with spermatocytes and round spermatids indicating a healthy reproductive status in males. However, the testis of the envenomed group revealed a tubular atrophy, depletion of spermatogenic cells, distorted germinal epithelium and necrosis of the spermatogenic cells (Fig. 7). On the other hand, lesion was not observed in the epididymis of control rats however, a prominent mucosal epithelium with little luminal content was noticed in epididymis of envenomed group (Fig. 8). Furthermore, a fused neuronal degeneration, ischaemic neuronal necrosis and gliosis was observed in brain tissues of envenomed rats while there was no observable lesion in brain tissues of the control (Fig. 9).

4. Discussion

Snake venom toxins are known to initiate wide spectrum of biological activities and cause different metabolic disorders by altering cellular inclusions and enzymatic activities of different organs and systems of the body following snakebite envenoming [31,32]. This current study unraveled reproductive and neural toxicities due to *N. nigricollis* envenoming. The post envenoming behaviour of the envenomed animals, weight loss due to loss of appetite and resultant to a mortality may be attributed to toxins present in the venom as earlier observed by Adeyi et al. [17]. Findings from this study showed that the venom toxins induced significant decrease in testicular weight and organo-somatic index of the envenomed rat which could arise from decrease in the number of epithelial spermatogenic cells nesting the seminiferous tubules, through testicular ischemia and necrosis, leading to loss of testicular weight [33]. Significant decrease in relative testicular weight in this study is an evidence of testicular toxicity as earlier observed in other animal studies due to the effects of toxicants [33,34].

Cells of the body are composed of membrane receptors which are sensitive to the action of snake venoms but often targeted by venom components. Sperm cells are types targeted by animal venoms and sensitivity of sperm to venom components has been reported as their cells contain a notorious rich repertoire of ion channels and membrane receptors, making them a priori susceptible interesting targets for the

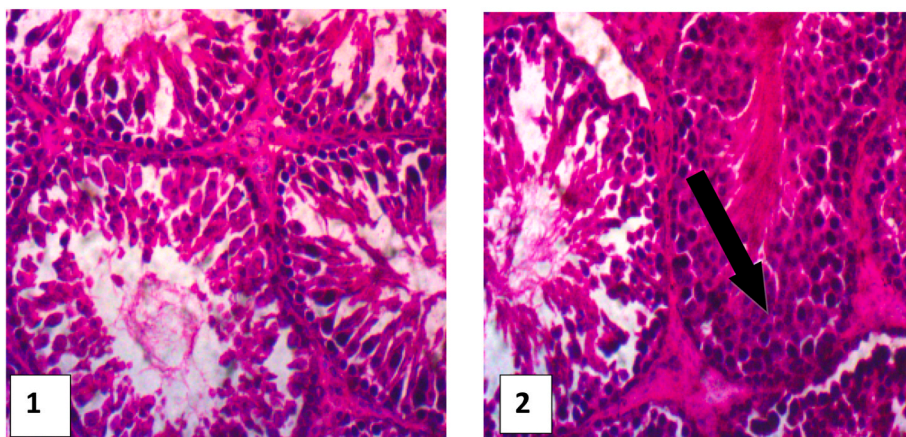


Fig. 7. Histological examination of the testis **Group 1 (Control):** No lesion, **Group 2 (Envenomed):** Tubular atrophy, distortion of germinal epithelium and necrosis of the spermatogenic cells. HE x400.

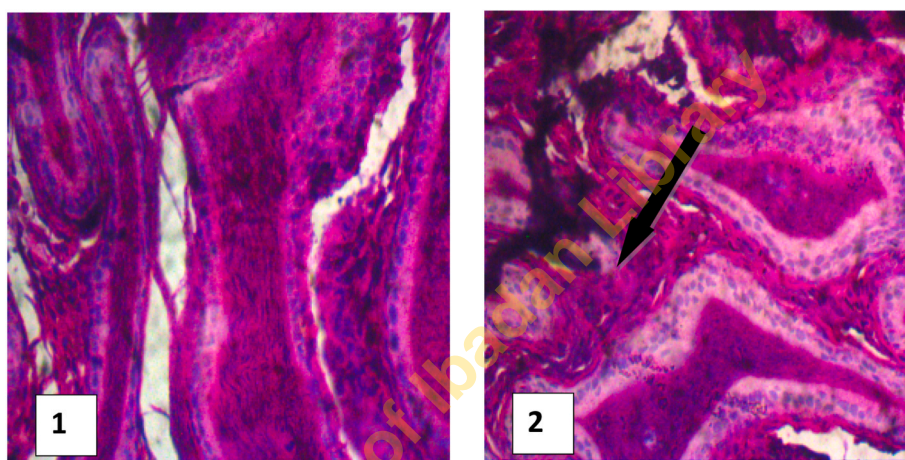


Fig. 8. Histological examination of the epididymis **Group 1 (Control):** No lesion, **Group 2 (Envenomed):** The mucosal epithelium are prominent with little luminal content. HE x400.

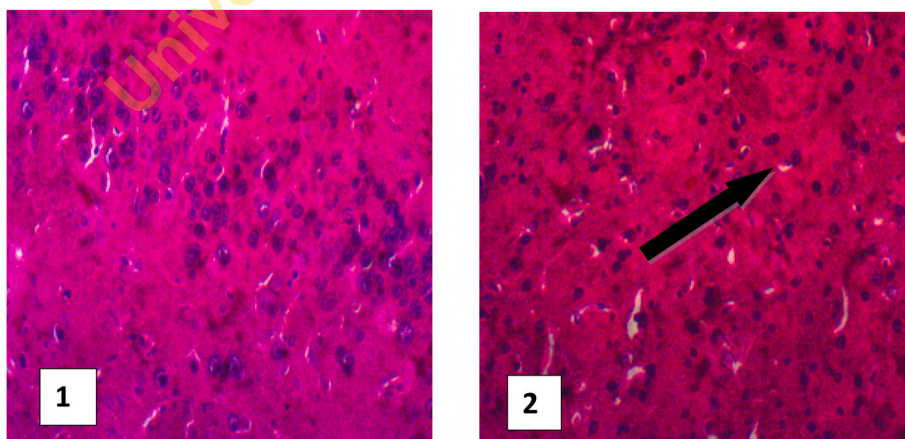


Fig. 9. Histological examination of the brain **Group 1 (Control):** No lesion, **Group 2 (Envenomed):** Ischaemic neuronal necrosis and gliosis.

action of venom components [35,36]. Consequently, the observed significant reduction in motile sperm, count, and volume in envenomed rats can be attributed to the action *N. nigricollis* venom toxins through initiating impairment of spermatogenesis in the testes. The toxic enzymes present in *N. nigricollis* venom are cytotoxic majorly phospholipase A2 (PLA2), an enzyme that hydrolyze the sn-2 fatty acid acyl ester

bond of phosphoglycerides to free fatty acid and lysophospholipids specifically with plasma membranes and catalyzes the breakdown of phospholipids within their structure [2,37]. Therefore, PLA2 breakdowns plasma membranes of sperms and contributes to decreased sperm counts and motility. Interestingly, inhibition of male sperm motility and acrosome reaction by action of venom phospholipases A2 have been

reported [38]. It is known that sperm motility is a key requirement for fertilization to occur and cases of infertilities are attributed to defective immotile sperm or altered acrosome reaction arising from sperm cells abnormalities [39]. In this study, a significant increase in abnormal sperm cells induced by the venom was noticed which is in tandem with previous studies [15]. Although, the mechanism of sperm abnormality induction was not yet ascertained but this may be due to excessive free radicals particularly Hydroxyl (OH^\cdot) generated by the venom toxins interacting with the DNA in the sperm heads. Also, OH^\cdot generated by the venom may interact with biomolecules such as the DNA, proteins and lipids to induce oxidative damage [40] however, further investigation is required to ascertain the exact mechanism.

The administration of *N. nigricollis* venom-induced harmful reproductive effects on hormone profiles as evidenced by the decrease in serum testosterone including reduction in levels of LH and FSH which are essential hormones for activating the process of spermatogenesis. FSH binds to Sertoli cells and stimulates testicular fluid production while LH is produced by gonadotropic cells to stimulate Leydig cells to produce testosterone which in turn plays an important role in the development of male reproductive tissues such as testis [41,42]. The decline in the concentration of testosterone post-venom injection indicates harmful changes in the Leydig interstitial cells of testes, which are responsible for testosterone biosynthesis and secretion [43]. Furthermore, the reduction in sperm count as earlier noticed could be attributed to the decline in the concentration of testosterone through induction of Leydig cell damage that disrupts testosterone synthesis.

Oxidative stress may be a result of excessive reactive oxygen species generation or failure of the cellular antioxidant system [11]. Reports have documented that increased concentration of polyunsaturated fatty acids (docosahexaenoic acid) and low expression levels of antioxidants make spermatozoa highly susceptible to ROS attacks resulting in lipid peroxidation [44]. In this current study, *N. nigricollis* venom toxins caused up-regulation of lipid peroxidation levels in testis, epididymis and brain tissues. However, there was low responses in levels of GSH and catalase activity in testis, epididymis and brain tissues indicating the venom caused an elevation of oxidative stress indicators such as lipid peroxidation and damaged the oxidant system. Glutathione plays an important role in system detoxification process and found mainly in the cell cytosol as they are known to be cell's natural antioxidant that neutralizes free radicals formed in cells [11] while catalase subsequently helps in detoxification of H_2O_2 to water as protective mechanism against lipid peroxidation [45]. Malfunctioning of the oxidant system as observed in this study aligned with previous interpretation of the consequences GSH deficiency in the body system as a result of oxidant damage and elevated lipid peroxidation which in turn leading to cell damage [11,46,47].

Pro-inflammatory cytokines are produced by testicular somatic and spermatogenic cells, both under normal conditions to control immune cell function within the testis, stimulate and maintain spermatogenesis or in response to inflammatory stimuli [48]. Also, excess production of pro-inflammatory cytokines may result in physiological damages as they are known to provoke inflammation and infections responses thereby contributing to transformation from acute to chronic inflammation and development of autoimmune reaction [49]. In this study, IL1 and TNF produced in reproductive organs of the envenomed rats was more evident compared to control an indication of possible reproductive organs inflammation due to cytokines imbalances which may contribute to infertility [49]. Up-regulation of pro-inflammatory cytokines by *N. nigricollis* venom as observed in this study aligned with our previous studies using cobra venom [50].

The observed reduction in sperm parameters was consistent with the histopathological examination of the testis and epididymis that showed significant harmful tissues changes with tubular atrophy and distorted germinal epithelium occurring in testicular tissue while a prominent mucosal epithelium with little luminal content was noticed in epididymal tissue which could possibly be due to venom induced oxidative

stress. In addition, degenerated reproductive organ tissue ascribed to snake venom toxins have been documented [14].

Access of toxins to the nervous tissues enhances the possibility of a direct neurotoxic effect as neurotoxicity ultimately depends on the ability of the substance to bind to neural tissue targets and interfere with functional or structural integrity [51]. The assessment of the venom toxicities on the brain of envenomed rats was based on mechanism of action exhibited by *N. nigricollis* venom as neurotoxins in cobra venom are known to attack the central nervous system [6], disrupt its functions, facilitates nervous dysfunction and shutdown resulting to tetany and ultimately death.

The mammalian nervous system has functional design features that predispose it to chemical perturbation. Consequently, neurological dysfunction is among the most common of the toxic responses of humans to toxicants and brain is a major target organ for some toxins [51]. This may inform the observed increase in oxidative stress markers resulting from excessive generation of reactive oxygen species (ROS) and up-regulation of pro-inflammatory cytokines production as revealed in the brain tissues of envenomed rats. In addition, toxins in *N. nigricollis* venom induced significant decrease in the brain weight and brain index compared to the control an indication the toxins have a direct interaction with the brain tissues as evident with various histological alterations noticed on brain tissues of envenomed rats which was in consonance with findings from our previous studies on cobra venom [50]. The alterations noticed on histological and biochemical composition of brain tissues after envenomation is an indication of brain toxicity due to direct effects of the venom toxins on the brain. This may occur as a result of damage to the blood brain barrier and consequently disrupt the functions of the nervous system.

It should be noted that reproductive functions are ultimately regulated by the hypothalamus-pituitary-gonadal (HPG) axis of the nervous system mainly the brain [52]. The role of the brain as the primary regulator of neuroendocrine and reproductive function through brain's responsiveness to hormonal feedback [53] makes it an important organ to consider when studying reproductive and nervous system-disrupting toxicants. The hypothalamus, located at the base of the brain, is especially vital for regulation of endocrine function as it serves as an interface between the nervous and endocrine systems [53] including the reproductive system. Consequently, alterations of hormone levels along with effects on the reproductive system caused by exposure to toxicants could manifest due to disruptive structure and function of the brain. However, the mechanism of *N. nigricollis* venom toxins altering the reproductive and neurological functions in the envenomed rats may not yet be ascertained in this present study, but results obtained is worthy of attention and provides caution to effectively treat snakebite envenomed victims using a standard antivenom to avoid systemic toxicity which may manifest post-envenoming if proper treatment is not administered.

5. Conclusion

This study demonstrated that *N. nigricollis* venom is capable of exhibiting serious toxic effects on nervous and male reproductive system as the venom alters biochemical compositions of the brain, decreased reproductive hormones levels and increased sperm abnormalities combined with reduced motile sperm and count. These observed effects or in combination are major factors reportedly responsible for nervous and reproductive dysfunctions which will have an important implication to public health most especially infertility challenges. The information obtained from this study may provide a better knowledge of other clinical implications of ineffective treatment of snakebite envenomed patients most especially in rural areas and further drive focus on development and implementation of a new therapeutic strategy for the treatment of snakebite envenoming.

Funding

None received.

Declaration of competing interest

None to declare.

CRedit authorship contribution statement

Babafemi Siji Ajisebiola: Conceptualization, Methodology, Formal analysis, Project administration, Investigation, Resources, Writing – original draft, Writing – review & editing, Supervision. **Olukemi Blessing Adeniji:** Formal analysis, Laboratory analysis, Resources, Investigation. **Adewale Segun James:** Formal analysis, Laboratory analysis, Investigation, Writing – review & editing. **Babajide O. Ajayi:** Formal analysis, Laboratory analysis, Methodology, Resources, Investigation. **Akindele Oluwatosin Adeyi:** Conceptualization, Methodology, Project administration, Validation, Supervision, Writing – review & editing. All authors have read and approved the final manuscript.

References

- Williams HF, Hayter P, Ravishankar D, Baines A, Layfield HJ, Croucher L, Wark C, Bicknell AB, Trim S, Vaipuri S. Impact of *Naja nigricollis* venom on the production of methaemoglobin. *Toxins* 2018;10:539. <https://doi.org/10.3390/toxins10120539>.
- Warrell DA. Snake bite. *Lancet* 2010;375:77–88.
- Cher CDN, Armugam A, Zhu YZ, Jeyaseelan K. Molecular basis of cardiotoxicity upon cobra envenomation. *Cell Mol Life Sci* 2005;62:105–18.
- Tohamy AA, Mohamed AF, Abdel Moneim AE, Diab MSM. Biological effects of *Naja haje* crude venom on the hepatic and renal tissues of mice. *J King Saud Univ Sci* 2014;26:205–12.
- Kang TS, Georgieva D, Genov N, Murakami MT, Sinha M, Kumar RP, Kaur P, Kumar S, Dey S, Sharma S, Vrieland A, Betzel C, Takeda S, Arni RK, Singh TP, Kini RM. Enzymatic toxins from snake venom: structural characterization and mechanism of catalysis. *FEBS J* 2011;278:4544–76.
- Al-Mamun MA, Hakim MA, Zaman MK, Hoque KMF, Ferdousi Z, Abu Reza M. Histopathological alterations induced by *Naja naja* crude venom on renal, pulmonary and intestinal tissues of mice model. *Br Biotechnol J* 2015;6:119–25.
- Luiselli L, Angelici FM, Akani GC. Comparative feeding strategies and dietary plasticity of the sympatric cobras *Naja melanoleuca* and *Naja nigricollis* in three diverging Afrotropical habitats. *Can J Zool* 2002;80:55–63.
- Yusuf PO, Mamman M, Ajagun E, Suleiman MM, Kawu MU, Shittu M, Isa HI, Tauheed M, Yusuf A. Snakes responsible for bites in North-Eastern Nigeria – a hospital based survey. *J. Environ. Sci. Toxicol. Food Technol.* 2015;9:118–21.
- Habib AG. Public health aspects of snakebite care in West Africa: perspectives from Nigeria. *J Venom Anim Toxins Incl Trop Dis* 2013;19:27.
- WHO. Snakebite envenoming: a strategy for prevention and control. Geneva: World Health Organisation; 2019. Licence: CC BY-NC-SA 3.0 IGO.
- Al-Sadoon MK, Abdel-Moneim AE, Bauomy AA, Diab MSM. Histochemical and Biochemical effects induced by LD50 of *Cerastes cerastes gasperetti* crude venom in mice. *Life Sci J* 2013;10:4.
- Fox JW, Serrano SM. Exploring snake venom proteomes: multifaceted analyses for complex toxin mixtures. *Proteomics* 2008;8:909–20.
- Maria DA, Vassão RC, Ruiz IRG. Haematopoietic effects induced in mice by the snake venom toxin jararhagin. *Toxicon* 2003;42:579–85.
- Kumar JR, Basavarajappa BS, Arancio O, Aranha I, Gangadhara NS, Yajurvedi HN, et al. Isolation and characterization of “Reprotoxin”, a novel protein complex from *Daboia russelii* snake venom. *Biochimie* 2008;90:1545–59.
- Fernandes FH, Bustos-Oregon E, Matias R, Dourado DM. *Crotalus durissus* sp. rattlesnake venom induces toxic injury in mouse sperm. *Toxicon* 2018;153:17–8.
- Alberto-Silva C, Franzin CS, Gilio JM, Bonfim RS, Querobino SM. Toxicological effects of bioactive peptide fractions obtained from *Bothrops jararaca* snake venom on the structure and function of mouse seminiferous epithelium. *J Venom Anim Toxins Incl Trop Dis* 2020;26:e20200007.
- Adeyi AO, Ajisebiola BS, Adeyi OE, Alimba GC, Okorie UG. Antivenom activity of *Moringa oleifera* leaf against pathophysiological alterations, somatic mutation and biological activities of *Naja nigricollis* venom. *Scientific African* 2020;8:e00356.
- Abdel Ghani LM, Elasmer MF, Abbas OA, Rahmy TR. Histological and immunohistochemical studies on the nephrotoxic effects of *Naja nigricollis* snake venom. *Egypt. J. Nat. Toxin.* 2010;7:29–52.
- National Research Council. Guide for the care and use of laboratory animals. Washington, DC, USA: National Academies Press; 2010.
- Adler I. Comparison of the duration of spermatogenesis between male rodents and humans. *Mutat Res* 1996;352:169–72.
- Rowett HGO. Dissecting guides of rats with notes on mouse. 111. London: Bulter and tanner LTD.; 1997. p. 5–23.
- Yokoi K, Uthus EO, Nielsen FH. Nickel deficiency diminishes sperm quantity and movement in rats. *Biol Trace Elem Res* 2003;93:141–54.
- Freund M, Carol B. Factors affecting haemocytometer count of sperm concentration in human semen. *J Reprod Fertil* 1964;8:149–55.
- World Health Organisation. WHO laboratory manual for the examination and processing of human semen. fifth ed. Geneva: World Health Organisation; 2010. <http://www.who.int/iris/handle/10665/44261>.
- Wyrobek AJ, Gordon LA, Burkhardt JG, Francis MW, Kapp RW, Letz G, Whorton MD. An evaluation of the mouse sperm morphology test and other sperm tests in non-human mammals. A report of the United States Environmental Protection Agency Gene-Tox Program. *Mutat Res Rev Genet Toxicol* 1983;115:1–72.
- Ohkawa H, Ohishi N, Yagi K. Assay for lipid peroxides in animal tissues by thiobarbituric acid reaction. *Anal Biochem* 1979;95:351–8.
- Aebi H. Catalase in vitro. *Methods Enzymol* 1984;105:121–6.
- Ellman GL. Tissue sulfhydryl groups. *Arch Biochem Biophys* 1959;82:70–7.
- Yacoub T, Rima M, Sadek R, Hleihel W, Fajloun Z, Karam M. *Montivipera bornmuelleri* venom has immunomodulatory effects mainly up-regulating pro-inflammatory cytokines in the spleens of mice. *Toxicol Rep* 2018;5:318–23.
- Drury RAD, Wallington EA. Carleton's histological technique. New York: Oxford University, Press; 1981.
- Aiesenberg AC. The glycolysis and respiration of tumors, 21. Acad. Press; 1981. p. 314–7.
- Theakston RD. The application of immunoassay techniques, including enzyme-linked immunosorbent assay (ELISA), to snake venom research. *Toxicon* 1983;21:341–52.
- Zhu Q, Li X, Ge RS. Toxicological effects of cadmium on mammalian testis. *Front Genet* 2020;11:527.
- Somade OT, Ajayi BO, Adeyi OE, Adeshina AA, James AS, Ayodele PF. Ethylene glycol monomethyl ether-induced testicular oxidative stress and time-dependent up regulation of apoptotic, pro-inflammatory, and oncogenic markers in rats. *Metabolism Open* 2020;7:100051.
- Abd El-Aziz TM, Jaquillard L, Bourgoin-Voillard S, Martinez G, Triquigneaux M, Zoukianian C, Combemale S, Hograindleur J, Al Khoury S, Escoffier J, Michelland S, Bulet P, Beroud R, Seve M, Arnoult C, De Waard M. Identification, characterization and synthesis of walterospermin, a sperm motility activator from the Egyptian black snake *Walterinnesia aegyptia* venom. *Int J Mol Sci* 2020;21:7786.
- Martinez G, Hograindleur JP, Voisin S, Abi Nahed R, Abd El Aziz TM, Escoffier J, Bessonnat J, Fovet CM, De Waard M, Hennebicq S, et al. Spermaurin, an La1-like peptide from the venom of the scorpion *Scorpio maurus palmatus*, improves sperm motility and fertilization in different mammalian species. *Mol Hum Reprod* 2017;23:116–31.
- Amin A. Dose-dependent effect of cobra venom on testes in mice. *J Biol Sci* 2007;7:294–9.
- Escoffier J, Couvet M, de Pomyers H, Ray PF, Seve M, Lambeau G, De Waard M, Arnoult C. Snake venoms as a source of compounds modulating sperm physiology: secreted phospholipases A2 from *Oxyuranus scutellatus scutellatus* impact sperm motility, acrosome reaction and in vitro fertilization in mice. *Biochimie* 2010;92:826–36.
- Curi SM, Ariagno JI, Chenlo PH, Mendeluk GR, Pugliese MN, Sardi Segovia LM, Repetto HE, Blanco AM. Asthenozoospermia: analysis of a large population. *Arch Androl* 2003;49:343–9.
- Ogunsuyi OM, Ogunsuyi OI, Akanni O, Alabi OA, Alimba CG, Adaramoye OA, Cambier S, Eswara S, Gutleb AC, Bakare AA. Alteration of sperm parameters and reproductive hormones in Swiss mice via oxidative stress after coexposure to titanium dioxide and zinc oxide nanoparticles. *Andrologia* 2020:e13758. 00.
- Jimoh A, Olawuyi T, Omotoso G, Oyewopo A, Dare J. Semen parameters and hormone profile of men investigated for infertility at midland fertility centre. *J Basic Appl Sci* 2012;8:110–3.
- Louvet JP, Mitchell HS, Ross GT. Effects of human chorionic gonadotropin, human interstitial cell stimulating hormone and human follicle stimulating hormone on ovarian weights in estrogen-primed hypophysectomized immature female rats. *Endocrinology* 1975;96. 1179e1186.
- Smith LB, Walker WH. The regulation of spermatogenesis by androgens. *Semin Cell Dev Biol* 2014;30:2–13.
- Chen S, Allam JP, Duan YG, Haidl G. Influence of reactive oxygen species on human sperm functions and fertilizing capacity including therapeutical approaches. *Arch Gynecol Obstet* 2013;288:191–9.
- Younis H. Therapeutic potentials of superoxide dismutase. *Int J Health Sci* 2018;12:88–93.
- Bouchard G, Yousef IM, Barriault C, Tuchweber B. Role of glutathione and oxidative stress in phalloidin-induced cholestasis. *J Hepatol* 2000;32:550–60.
- Wang X, Kanel GC, De Leve LD. Support of sinusoidal endothelial cell glutathione prevents hepatic veno-occlusive disease in the rat. *Hepatology* 2000;31:428–34.
- Loveland KL, Klein B, Pueschl D, Indumathy S, Bergmann M, Loveland BE, Hedger MP, Schuppe HC. Cytokines in male fertility and reproductive pathologies: immunoregulation and beyond. *Front Endocrinol* 2017;8:307.
- Trunov A, Obukhova O, Gorbenko O, Shvayk A, Trunova L. Cytokines and infertility influence of cytokines and local inflammation in women of reproductive age with infertility. *J. Cytokine Biol.* 2016;1:1.
- Adeyi AO, Ajisebiola BS, Adeyi OE, Adekunle O, Akande OB, James AS, Ajayi BO, Yusuf PO, Idowu BA. *Moringa oleifera* leaf fractions attenuated *Naja haje* venom-induced cellular dysfunctions via modulation of Nrf2 and inflammatory signalling pathways in rats. *Biochemistry Biophysics Rep.* 2021;25:100890.

- [51] Spencer PS, Lein PJ. Neurotoxicity. In: Wexler P, editor. Encyclopedia of toxicology. third ed., 3. Elsevier Inc., Academic Press; 2014. p. 489–500.
- [52] Schally AV, Kastin AJ, Arimura A. The hypothalamus and reproduction. *Am J Obstet Gynecol* 1972;114:423–42.
- [53] Gore AC, Roberts JL. Neuroendocrine systems. *Fundamental neuroscience*. second ed. New York: Academic Press; 2003.

University of Ibadan Library