

# Distribution and Characteristics of Endometriotic Lesions in South- Western Nigeria: A Single Institutional Experience

Mustapha Akanji Ajani\*, Ayodeji Salami, Ifeanyichukwu Dupe Nwanji,  
Aralola Adepeju Olusanya, Oluwaseun Ebenezer Fatunla

Department of Pathology, University College Hospital, Ibadan

## ABSTRACT

**Background:** Endometriosis poses a significant burden mainly to women of child bearing age. Historically, endometriosis was thought to be of low prevalence among African women. However, recent studies have documented an increased prevalence than previously thought. This study aimed to determine the distribution and characteristics of endometriotic lesions among Nigerian women.

**Methods:** A retrospective study of all histologically diagnosed cases of endometriosis from the records of the Department of Pathology, University College Hospital, Ibadan from 1st January, 1997 to 31st October, 2018. The age of the women, location and distribution of the lesions were analysed.

**Results:** A total of 85 cases of endometriosis were diagnosed histologically in the period under review. The mean age was 35 years with an age range of 18 to 52 years. The most commonly affected age groups were those between 30-39 years (47.1%) and 20-29 years (30.6%). The most commonly affected site was the ovary (58.8%) followed by the umbilicus (11.9%) and fallopian tubes (9.4%). Fourteen patients (28%) had bilateral ovarian involvement. Left sided ovarian lesions predominated (61.1% versus 38.9%). Eighteen (21.2%) patients had lesions at more than one site frequently involving both ovaries.

**Conclusion:** Endometriosis affected mainly women of childbearing age with particular predilection for the ovaries. Endometriosis affecting the umbilicus is not uncommon among Nigerian women.

## INTRODUCTION

Endometriosis is a disease of the female genital system principally characterized by the presence of endometrial tissue, consisting of glands and/or stroma outside the uterus. The ovary is the most common site for endometriosis. Other commonly affected sites include pelvic peritoneum and rectovaginal septum. Rarely lesions have been identified on the umbilicus, diaphragm, pleura and pericardium.<sup>1</sup> The definitive diagnosis of endometriosis is based on histologic examination of tissue biopsies. The histologic diagnosis of endometriosis is typically based on the presence of endometriotic glands and stroma in extra-uterine biopsy tissue.

Endometriosis remains an intriguing disorder for at least two reasons. One is the uncertain aetiology. Several theories on its aetiology have been proposed such as retrograde menstruation, coelomic metaplasia of embryonic cell rests, induction, lymphatic and vascular dissemination. All proposed mechanisms have their deficiencies.<sup>2</sup> The other reason is the uncertain behaviour of the endometriotic lesions. While not associated with catabolic state typically seen in a malignancy, endometriosis shares features with malignant tumours such as metastasis (if the theory of

### \*Corresponding Author:

Dr Mustapha A. Ajani, Department of Pathology, University College Hospital Ibadan. Email: ajanimustapha42@gmail.com, Tel: +2348039125255

**Keywords:** Endometriosis, Ibadan, Nigeria, ovary, umbilicus

lymphatic and vascular dissemination is to be believed), local invasiveness and possible clonal origin from a single epithelial cell.<sup>3</sup> To add to this already complex nature, both ovarian and extra-ovarian endometriosis have been associated with a low but definite risk of malignant transformation.<sup>4,5</sup>

Endometriosis poses a significant public health problem with an estimated 6% to 10% of reproductive-aged women and up to half of women with infertility and chronic pelvic pain suffering from the condition in Caucasian studies.<sup>6</sup> It also represents a significant proportion of gynecological surgeries with attendant costs and sequelae and is a major cause of disability and reduced quality of life in women and teenage girls.<sup>7</sup>

Historically, the prevalence of endometriosis was said to be low among African women. In the classic study by Aimakhu and Osunkoya in 1971 among gynaecologic surgical patients at the University College Hospital, Ibadan, only 7 patients were identified over a 17 and a half year period with a prevalence of 0.24% of gynaecologic laparotomies.<sup>8</sup> Interestingly, a similar study among Hausa/Fulani women published 1979 found a much higher prevalence of 8.2%.<sup>9</sup> Recently, a cross sectional study utilized laparoscopy to determine the prevalence of endometriosis among selected Nigerian women at the University of Ibadan. Among the women investigated, close to half (48%) suggesting a higher prevalence than previously documented. The prevalence was higher in women with complaints of dysmenorrhea.<sup>10</sup>

With respect to the anatomic distribution of endometriotic lesions, an observational study in Greece found the ovary as the commonest site (65%) followed by the utero-sacral ligaments (USL) (46%), the ovarian fossa (32%), the pouch of Douglas (30%) and the bladder (21%). The left side was predominant for most. The mean age of patients was 33 years.<sup>11</sup> Another study from South Korea reported a predominance of ovarian lesions (96%), followed by the soft tissue (3%), gastrointestinal tract and urinary tract (both less than 1%). The mean age of patients was 36 years.<sup>12</sup>

A review of published literature regarding the anatomic distributions of endometriosis among Nigerian women revealed only a few case reports. We aimed to document our experience at the Department of Pathology in the recent years regarding the distribution and characteristics of endometriotic lesions.

## METHODS

All cases of histologically diagnosed endometriosis from the files and records of Department of Pathology, University College Hospital, Ibadan, Nigeria from 1st January, 1997 to 31st October, 2018 were reviewed. The data retrieved included the age of the women and location of the lesions. Relevant slides were retrieved from the archives of the department and reviewed where necessary. The data obtained was analysed using the Statistical Package for Social Sciences, version 23 (SPSS 23). Continuous variables were expressed as means while frequencies of categorical data as n (%).

## RESULTS

There were 85 histologically diagnosed cases of endometriosis during the period under review. The mean age of the patients was 35 years. The youngest was 18 years and the oldest was 52 years. Most patients were in the reproductive age group (Table 1).

**Table 1: Age Distribution of Patients**

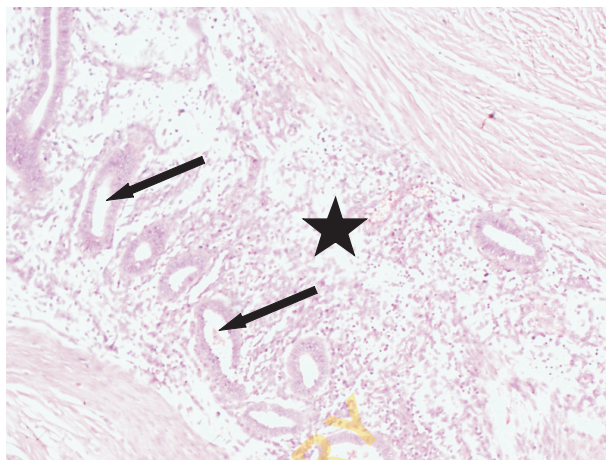
| AGE GROUP (N=85) | FREQUENCY (%) |
|------------------|---------------|
| 10-19            | 1 (1.1)       |
| 20-29            | 26 (30.6)     |
| 30-39            | 40 (47.1)     |
| 40-49            | 14 (16.5)     |
| 50-59            | 4 (4.7)       |

The commonest site of endometriosis was the ovary in 50 (58.8%) patients (Table 2). Fourteen patients (28%) had bilateral ovarian involvement while the others with ovarian endometriosis had unilateral lesions (Figure 1). Sidedness could not be determined for 18 patients due to lack of information. Left sided ovarian lesions however predominated (11 patients with left sided ovarian

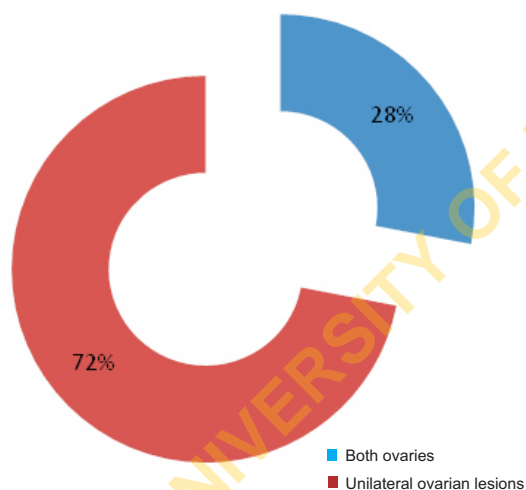
lesions versus 7 patients with right sided ovarian lesions).

**Table 2: Distribution of Endometriotic Lesions**

| LOCATION            | FREQUENCY (%) N=85 |
|---------------------|--------------------|
| Ovary               | 50 (58.8)          |
| Umbilicus           | 10 (11.8)          |
| Fallopian tube      | 8 (9.4)            |
| Skin                | 6 (7.1)            |
| Omentum             | 5 (5.9)            |
| Colon               | 4 (4.7)            |
| Bladder             | 4 (4.7)            |
| Cervix              | 2 (2.4)            |
| Inguinal lymph node | 2 (2.4)            |



**Figure 2: Photomicrograph of the umbilical nodule showing endometrial glands (arrows) and endometrial stroma (asterisk). (Haematoxylin and eosin stains, X100)**



**Figure 1: Distribution of Endometriotic Lesions in the Ovaries**

A sizeable proportion of patients (11.8%) had umbilical endometriosis (Figure 2). Four patients (4.7%) had lesions involving the colon. The appendix was the location in two of the four patients with colonic involvement. These patients presented with features suggestive of appendicitis. In one of the patients, endometriosis simulated a colonic carcinoma with luminal obstruction resulting in a right hemi-colectomy.

A total of 18 patients had features of endometriosis in biopsies from more than one anatomic location. The most common combination was both ovaries in 14 patients. In one patient with bilateral ovarian lesions and an ileal mass, endometriosis simulated a metastatic tumor. Histology of the lesions however revealed bilateral ovarian endometriosis and a foreign body granulomatous inflammatory lesion of the ileal serosa due to foreign body introduced from a previous surgery.

**DISCUSSION**

A total of 85 patients were histologically diagnosed with endometriosis over a 22 year period of the study with a mean age of 35 years. The commonest site of endometriosis was the ovary with a sizable proportion of patients having umbilical lesions. As much as 28% of patients had bilateral ovarian involvement. Left sided ovarian lesions predominated. About a fifth of patients had lesions involving more than one anatomic site, the commonest combination being both ovaries. In at least 2 cases, endometriosis simulated a malignant neoplasm.

The average number of cases seen per year was about 4 patients. This suggests an increasing prevalence of

endometriosis especially when compared with an average of one patient every other year in the older study from this same centre.<sup>8</sup> The factors responsible for this apparent increase in incidence may include increasing access to tertiary health care. Even so, a total of 85 cases over a 22 year period may not truly tell the real picture of endometriosis among Nigerian women. Most patients in our series presented primarily because of a palpable mass which was excised and sent for histological examination. It is therefore likely that many women without a palpably enlarged mass but with symptoms of chronic pelvic pain or infertility were not examined or biopsied. This may be attributable to peculiarities in beliefs regarding chronic/cyclical pelvic pain. In keeping with this view, Fawole *et al* documented a prevalence as high as 48% during laparoscopy among women with infertility and chronic pelvic pain.<sup>10</sup>

Endometriosis is mainly a disease of women of reproductive age. This is reflected in the age distribution of the patients. Most patients were aged 30-39 and more than 75% of patients were aged between 20-40 years. The youngest patient was an 18 year old patient with an ovarian cyst. The most common site affected by endometriosis was the ovary. A similar prevalence was observed in studies by Audebert *et al* and Lee *et al*.<sup>11,12</sup> Close to a third of patients had bilateral ovarian involvement underscoring the implications of endometriosis as a cause of infertility in the African woman. The prevalence of 28% of bilateral ovarian lesions compares favourably with 32.5% documented by Lee *et al*. For unilateral lesions, there was a predominance of left sided ovarian lesions compared to lesions on the right (61.1% versus 38.9%). A similar predominance of left sided lesions was documented by Audebert *et al*.<sup>11,12</sup>

Interestingly, the second most common site affected by endometriosis was the umbilicus. Umbilical endometriosis is traditionally a rare lesion. Many of the patients presented with symptoms of umbilical swelling and/or discharge. Considering that as many

as 11% of patients in our series presenting with umbilical lesions, it may be safe to conclude that umbilical endometriosis is indeed not a rare lesion in the Nigerian woman.

The involvement of gastrointestinal structures underscores the importance of endometriosis as a great mimicker and should be considered in differential diagnosis. The two patients with appendiceal endometriosis presented with features suggestive of appendicitis. In another patient, endometriosis simulated a colonic carcinoma with luminal obstruction resulting in a right hemicolectomy. Lesions involving the skin were seen in about 7% of patients. Most of these patients had lower abdominal surgical scars from previous biopsies and this may lend some credence to the theory of transplantation as aetiology of endometriosis.

Just over a fifth of patients in this series had histologically diagnosed endometriosis involving more than one site. The most common combination involved both ovaries as earlier stated. Such lesions were apt to be mistaken for a malignant process resulting in less conservative surgical techniques. One such patient had bilateral ovarian cystic lesions with an ileal mass. Excisional biopsies revealed bilateral ovarian endometriosis and a foreign body granulomatous inflammation of the ileal serosa. Patients with less conservative surgeries may be at higher risk for infertility and other post-surgical sequelae.

## CONCLUSION

This study contributes to the growing narrative that endometriosis is not as rare a disease among Africans as may have been suggested by early studies. Indeed a significant proportion of patients have lesions involving more than one site and in some cases mimicked cancers. In addition, endometriosis should be suspected in any women of reproductive age with an umbilical mass.

## REFERENCES

1. Giudice LC. Clinical practice. Endometriosis. *N Engl J Med.* 2010 Jun 24;362(25):2389-98. PubMed PMID: 20573927. Pubmed Central PMCID: PMC3108065. Epub 2010/06/25. eng.
2. Gazvani R. TA. New considerations for the pathogenesis of endometriosis. *Int J Gynaecol Obstet.* 2002;76:117–26.
3. Yano T JH, Yoshikawa H, et al. Molecular analysis of clonality in ovarian endometrial cysts. *Gynecol Obstet Invest.*47(suppl 1):41-6.
4. Brinton LA GG, Persson I, et al. Cancer risk after a hospital discharge diagnosis of endometriosis. *Am J Obstet Gynecol.* 1997;176:572–9.
5. Yantiss RK CP, Young RH. Neoplastic and preneoplastic changes in gastrointestinal endometriosis: a study of 17 cases. *Am J Surg Pathol.* 2000;24:513–24.
6. Eskenazi B WM. Epidemiology of endometriosis. *Obstet Gynecol Clin North Am.* 1997;24:235-58.
7. D'Hooghe T HL. Multidisciplinary centres/networks of excellence for endometriosis management and research: a proposal. *Hum Reprod.* 2006;21:2743-8.
8. Aimakhu VE, Osunkoya BO. Endometriosis externa in Ibadan, Nigeria. *American Journal of Obstetrics & Gynecology.* 1971;110(4):489-93.
9. Ekwempu CC, Harrison KA. Endometriosis among the Hausa/Fulani population of Nigeria. *Tropical and geographical medicine.* 1979 Jun;31(2):201-5. PubMed PMID: 505550. Epub 1979/06/01. eng.
10. Fawole AO, Bello FA, Ogunbode O, Odukogbe AT, Nkwocha GC, Nnoaham KE, et al. Endometriosis and associated symptoms among Nigerian women. *Int J Gynaecol Obstet.* 2015 Aug;130(2):190-4. PubMed PMID: 25935474. Epub 2015/05/04. eng.
11. Audebert A, Petousis S, Margioulas-Siarkou C, Ravanos K, Prapas N, Prapas Y. Anatomic distribution of endometriosis: A reappraisal based on series of 1101 patients. *European journal of obstetrics, gynecology, and reproductive biology.* 2018 Nov;230:36-40. PubMed PMID: 30240947. Epub 2018/09/22. eng.
12. Lee HJ, Park YM, Jee BC, Kim YB, Suh CS. Various anatomic locations of surgically proven endometriosis: A single-center experience. *Obstetrics & gynecology science.* 2015;58(1):53-8. PubMed PMID: 25629019. Epub 01/16.