

VITREO-RETINA

Pattern of Presentation of Patients with Macula Holes in Ibadan, South-Western, Nigeria

Babalola YO, Oluleye TS, Majekodunmi Ol, Ijaduola MA

Retina & Vitreous Unit, Department of Ophthalmology, University College Hospital, Ibadan, Nigeria.

Corresponding author: Babalola YO E-mail: yewandeb@gmail.com

Introduction: Macula holes are defects in the fovea involving the inner limiting membrane up to the photoreceptor layer.¹ Different local studies in Nigeria have shown prevalence of 6.6 % and 0.5% respectively.^{2,3} The common risk factors include age and female gender. Central visual loss is a common feature while bilaterality may be seen in about 30% of patients with macula holes.⁴

Aim: To describe the pattern of presentation, aetiology and risk factors of patients with macula holes seen at the retina clinic of a tertiary teaching hospital.

Methods: A retrospective study of all patients with macula hole diagnosed both clinically and with the aid of optical coherence imaging between the period January 2019 to December 2020. The demographic data, best corrected visual acuity, presenting complaints, and other relevant data relating to co-existing ocular & systemic comorbidities were retrieved from patients' case notes. Optical coherence tomography scans from the SOCT Copernicus machine where available were retrieved and interpreted. Statistical analysis was done with SPSS Version 23.

Results: Thirty - nine (4%) of 972 patients seen in the retina clinic during the study period had a diagnosis of macula hole. Twenty of the respondents were females and 19 were males giving a male to female ratio of 0.95:1. The mean age was 62.3 years (SD 15.1). Forty- three eyes were involved as five of the patients had bilateral macula holes. The age range of the respondents was 11 - 81 years.

The commonest presenting complaint was poor vision present in 31 (79.3%) respondents (Table 1), while 21 patients (53.8%) had noticed onset of symptoms less than a year prior to presentation. The best corrected visual acuity was equal to or less than 6/60 in 15 (48.4%) eyes and 6/60 -6/18 in 13 (41.9%) eyes respectively.

Idiopathic or age-related macula holes were the most common aetiology in 27 (69%) respondents (Table 2). Traumatic macula holes were seen in 6 patients (15.45%), especially in the younger age-group (< 40 years of age).

Thirty-nine (90.7%) of the 43 eyes in this study had stage 4 macula hole with intra-retinal cysts being the commonest finding on optical coherence tomography (Figure 1).

The commonest co-existing ocular morbidity was rhegmatogenous retinal detachment in 4 myopic eyes. Other ocular co-morbidities include proliferative sickle cell retinopathy (2),

Table 1: Presenting complaints of patients with macula holes

Presenting complaints	Frequency	Percentage (%)
Reduction in vision /Poor vision	31	79.3
Blurring of vision	4	10.4
Sudden visual loss	1	2.6
Eyeache	1	2.6
Trauma	2	5.0
Total	39	100

Table 2: Aetiology of macula holes among the study patients

Aetiology	Frequency	Percentage (%)
Idiopathic/Age related	27	69.2
Trauma	6	15.4
Myopia	3	7.7
Others (proliferative sickle cell retinopathy, toxoplasmosis)	3	7.7
Total	39	100

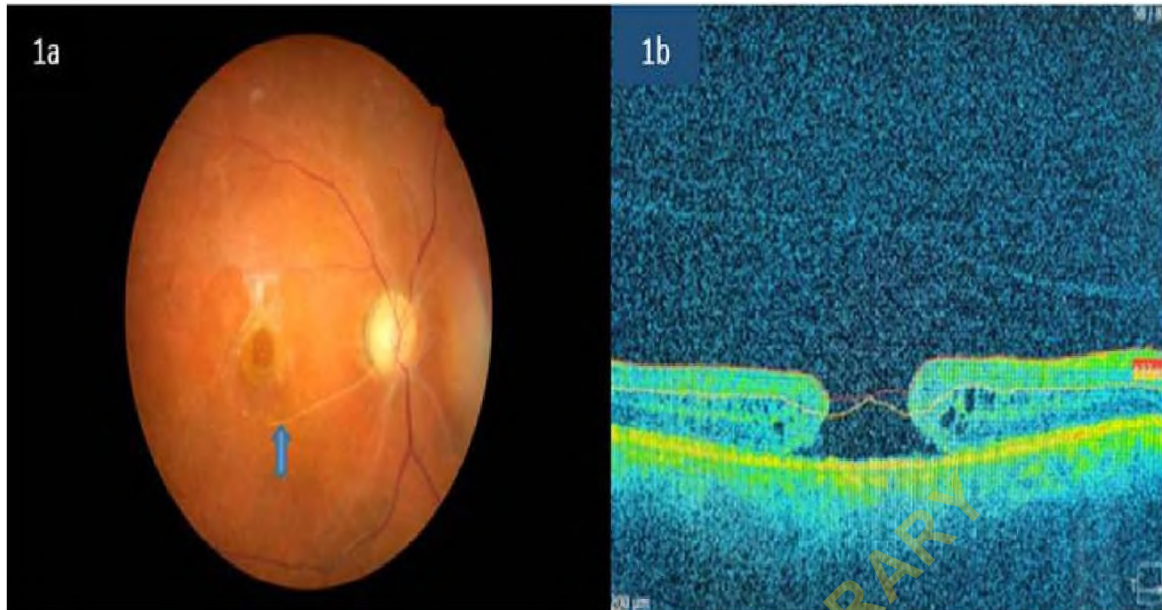


Figure 1: The fundus photograph and optical coherence tomography scan of a patient showing a full thickness macula hole with a complete posterior vitreous detachment, intraretinal cystic spaces and loss of the ellipsoid zone.

pseudophakia (2), inverse hypopyon (1) and mild NPDR amongst others.

Discussion and Conclusion: The prevalence of macula hole of 4% was similar to Benin but slightly lower than the figures of 6.6% and 6.4% in all patients with retinal disorders seen in Port-Harcourt and Ado-Ekiti respectively. The aetiology of the macula holes in our patients was mainly idiopathic with many of the patients being in the elderly age group and is comparable with similar studies in Nigeria.^{3,4,5}

Traumatic macula holes accounted for 15.5% of all the macula holes in our cohort of patients which is similar to findings from Port Harcourt.² Macula holes are a cause of presentation of patients with poor vision in the Retina clinic. Prompt diagnosis, management and examination of the other eye in patients with macula hole is essential.

References

1. Gass JDM. Idiopathic Senile Macular Hole Its Early Stages and Pathogenesis. *Arch Ophthalmol*. 1988;106(5):629-639
2. Fiebai, B. and Pedro-Egbe, C.N. (2015) Managing Macular Holes in a Developing Economy. *Open Journal of Ophthalmology*, 5, 139-144.
3. Ajayi IA, Omotoye OJ, Adegbehingbe S. (2020) Epidemiological Review of Macular Hole in

Ekiti, Southwestern Nigeria. *Open Journal of Ophthalmology*, 10, 276-282. doi: 10.4236/ojoph.2020.104030.

4. McDonnell PJ, Fine SL, Hillis AI. Clinical features of idiopathic macular cysts and holes. *Am J Ophthalmol* 1982;93(6):777-786.
5. Uhumwangho, O. and Itina, E. (2015) Retinal Diseases in a Tertiary Hospital in Southern Nigeria. *Journal of the West African College of Surgeons*. 5; (2) :1-16.