

Some Aspects of the Orbital and Ocular Morphometry of the African Giant Rat (*Cricetomys gambianus*, Waterhouse)

Olude, M.A¹., Olopade, J.O^{2*}., Igado, O.O²., Mustapha O.A¹., Akinloye A.K¹.

¹Department of Veterinary Anatomy, College of Veterinary Medicine, Federal University of Agriculture, Abeokuta, Nigeria

² Department of Veterinary Anatomy, Faculty of Veterinary Medicine, University of Ibadan, Nigeria

With 2 figures

Received January, accepted for publication March 2011

Abstract

This work was designed to investigate some aspects of the ocular and orbital morphometric characteristics of the African giant rat (*Cricetomys gambianus*, Waterhouse). 16 African giant rats consisting of 8 males and 8 female rats were euthanized; the eyeballs were enucleated and their skulls macerated to give 18 morphometric parameters. Student t-test and Pearson's correlation studies were used to analyze the obtained values. Correlation studies showed significance in the left orbital height as correlated against the right orbital index. The eyeball weight for right and left eyeballs were 0.16 g and 0.15 g. The mean eyeball circumference (anteroposterior and medio-lateral) measurements were 2.23 ± 0.01 cm and 2.02 ± 0.06 cm for the left and 2.06 ± 0.04 cm and 2.13 ± 0.03 cm for the right eyeball respectively. The mean right orbital length, right orbital height, left orbital height and the intercanthi width were 2.09 ± 0.02

cm, 1.21 ± 0.03 cm, 1.23 ± 0.03 cm and 0.93 ± 0.03 cm respectively but were all statistically higher ($p < 0.05$) in males than females exhibiting sexual dimorphism.

Keywords

Cricetomys gambianus Waterhouse, ocular, orbital, morphometric parameters, sexual dimorphism.

Introduction

African giant rats belong to the family Nesomyidae and order Rodentia. They are nocturnal rodents, omnivorous and feed on vegetation and invertebrates such as insects. They live in a variety of habitats ranging from arid to temperate areas (Ajayi, 1977). They have been reported to have olfactory powers utilized in the sniffing out of landmines and diagnosis of tuberculosis (Lindow, 2001). Information on the macro-anatomical features of the orbit and eyes of the African giant rat to the

best of our knowledge is nonexistent in the literature. There are many macro-anatomical investigations on organs and systems of rodents, including the rabbit, the guinea pig, the rat (Özkan et al., 1997), the mink (Dursun and Tıprıdamaz, 1989), the badger (Hidaka et al., 1998; Dinç, 2001) the porcupine (Yılmaz, 1998), the hedgehog (Özkan, 2005), the mole rat (Özkan et al., 2007). There has also been a recent increase in the contributions to the literature on the macro anatomy of African giant rats (Olude, 2009; Olude et al 2009; Olude and Olopade, 2010; Onyeanusi et al., 2009; Ibe et al 2010a; b). The aim of the present study was to investigate the orbital and ocular morphometry in the African giant rats in an attempt to contribute to information in this emerging field of the anatomical studies of this wild rodent.

Materials and methods

Sixteen adult African giant rats (8male, 8 females) with an average body mass of $730.00 \pm 41.91\text{gm}$ were used for this study. Eyeballs were preserved briefly in 0.9% saline after removal based on the enucleation techniques of Keller (1975) and Olopade et al (2005). The eyeballs were measured with threads soaked in normal saline, measured on linear rule and weighed on a Mettler® analytical balance. The methods of skull maceration and indices for orbitofacial measurements were adapted from

the works of (Onar 1999; Onar et al., 2001; Endo et al., 2002; Olopade and Onwuka, 2003; Olopade et al., 2005; Olopade (2006); Fernandes et al., 2008 and Olude et al., 2009) and described briefly below with some depicted in Figures 1 and 2.

Statistical analysis was carried out using the student t-test $P \leq 0.05$ and the Pearson's correlation test at $P < 0.05$ and $P < 0.01$.

Parameters of Orbital and Ocular Morphometry of the African Giant rat (*Cricetomys gambianus*, Waterhouse)

OL (Orbital length): Maximum length of the left and right orbits from rim to rim (includes maximum horizontal and maximum vertical diameters)

OC (Orbital circumference): Maximum circumference of the left and right orbits respectively from rim to rim. A twine was used to trace the orbits and the linear lengths determined

OH (Orbital height): Maximum height of the left and right orbits from the dorsal tip of the orbital rim to the ventral tip of the orbital rim.

ZGW (Zygomatic width): Maximum width across the zygomatic arches.

ICD (Intercanthal distance): Minimum distance between the medial margins of the orbits.

IO (Infraorbital foramen length): Greatest length across the left and the right infraorbital foramina

EW (Eyeball weight): Weight of the left and right eyeballs without the adnexa in grams.

EC/AP (Antero-posterior eye circumference): Maximum longitudinal circumference of the left and right eyeballs.

EC/ML (Mediolateral eye circumference): Maximum transverse circumference of the left and right eyeballs.

OI (Orbital index): $OH/OL \times 100$ for both right and left sides.

Results and Discussion

The results obtained in this study are shown in Table 1.

The orbit can be considered as a conical structure with a wide opening leading into an optic canal located at the apex. The base of the orbit is formed by a plane extending from the supraorbital rim and the jugal bone of the zygomatic bone vertically and the caudal part of the infraorbital rim and the caudal part of the zygomatic bone horizontally.

The mean left orbital height, length and circumference of the AGR in our study were different from the right, however the fact that the orbital index of both sides was 0.58 ± 0.01 shows a proportionately increased difference of the bony orbit of the left side over the right on both axis (length and height). In contrast however, the right eyeball was slightly lower in weight and size than the left counterpart indicating that heavier eyeballs do not neces-

sarily correspond to larger orbital osteometrics.

The right and left orbital circumferences, heights and lengths were greater in the males. However, only the right orbital length, right orbital height and the left orbital heights and intercanthi distance were statistically significant ($p < 0.05$). This may be due to size differences in the skull size (Olude, 2009) which may have been caused by developmental disparities (Fernandes et al., 2008). The significantly higher intercanthi distance in males suggests that males have a wider optic view and may translate to the fact that male rats are better adapted to escape from predators since the eyes are more laterally placed in males than in females. The sexual dimorphism observed in the four parameters afore mentioned could thus serve as sex determinants in anthropological studies. Similar observations of sexual dimorphism have been reported in the skull of the African giant rat (Olude, 2009); jaw and diastemal length of Sahel goats (Olopade and Onwuka, 2009), guinea pig (Farmer and German, 2004) and in Ferrets, where the males were about 17% , 22% and 12% larger than the females in skull length, maximum skull width and minimum frontal width respectively and the variations in the measurements were generally greater for the males than the female skeleton (He et al., 2002).

The mean eyeball weight in this study was 0.16 ± 0.01 gm. This is

less than the 3.00 gm in rabbits (Gellat, 1981), 0.27 gm in the Australian hopping mouse (*Notomys alexis*) (Smith, 1976) and 0.99 g in guinea pigs (Latimer, 1951), but greater than the 0.014-0.024 g in different strains of mice (Zhou and Williams 1999). The eyeball to body ratio was 1:4561 and can be used as comparative data with 1:130 in *Notomys alexis*, 1:1160 in albino rat (*Sprague-Dawley*) and 1: 1300 in an albino mouse (CLS-MON) (Smith, 1976).

The right and left antero-posterior eyeball circumference and the right mediolateral eyeball circumference were greater in males than in females but this did not translate into weight and eyeball weights between the sexes for the left and right eyeballs were similar.

There appears to be a proportional osteometric dimensional changes in the right and left orbit as evidenced by the moderately positively correlation of the ROI against LOI

This study presents morphometrics of the orbit and eyes of the African giant rat (*Cricetomys gambianus*, Waterhouse) and shows the presence of sexual dimorphism and symmetrical variations. Findings in this study will be useful in studies of the structure of the visual system of this rodent, anthropological studies and form part of the continuing effort to document various aspects of the anatomy of the African giant rat.

References

- Ajayi, S. (1977): Field observations on the Africangiant rat *Crice-tomys gambianus* in southern Nigeria. *East African Wildlife Journal*, 15(3): 191-198.
- Dinç, G. (2001): Macro-anatomical investigations on the skeletons of badger (*Meles meles*). III. Skeleton axiale. *Fırat Un. J. Health Sci.* 15: 175-178.
- Dursun, N and Tipirdamaz. S (1989): Etudes macro-anatomique-ment sur les os dusquelette du vison (*Mustela vison*). *J. Fac. Vet. Med. Univ. Selçuk.* 5: 13-27.
- Endo, H., Hayashi, Y., Yamazaki, K., Motokawa, M., Pei, J., Lin, L., Chou, C. and Oshida, T (2002): Geographical variation of the mandible size and shape in the wild Pig (*Suis scrofa*) from Taiwan and Japan. *Zoological studies* 41(4): 452-460
- Farmer M.A and German R.Z (2004): Sexual dimorphism in the craniofacial growth of the Guinea Pig (*Cavia porcellus*). *J. Morphol.*, 259:172-181
- Fernandes R.M, Antonio V.A, Roberto B.S, Danielle F.S, Gisele L.M, Marcio A.B and Cristiane FR (2008): Maternal malnutrition during lactation reduces skull growth in weaned rat pups: Experimental and morphometric investigation. *Anatomical*

- Science International 83: 123-130.
- Gelatt, K.W (1981): Veterinary Ophthalmology, 1st edition, Lea and Febiger London
- He, T., Friede, H., and Kiliaridis S (2002): Macroscopic and roentgenographic anatomy of the skull of the Ferret (*Mustela putorius furo*) Laboratory Animals 36:86-96.
- Hidaka, S., M. Matsumoto, H. Hiji, S. Ohsako, H. Nishinagawa (1998): Morphology and morphometry of skulls of raccoon dogs, *Nyctereutes procyonoides* and badgers, *Meles meles*, Vet. Med. Sci. 60, 161-167.
- Ibe, C. S., Onyeausi, B. I., Salami, S. O., Ajayi I.E. and Nzalak J.O (2010): On the structure of the spleen of the African giant rat (*Cricetomys gambianus*, Waterhouse 1840). Vet Research 3(4): 70-74
- Ibe, C. S., Salami, S. O. and Onyeausi, B. I.(2010) Macroscopic Anatomy of the Lower Respiratory System in a Nocturnal Burrowing Rodent: African Giant Pouched Rat (*Cricetomys gambianus*, Waterhouse 1840).Anatomia Histologia Embryologia (In Press)
- Keller, W.F (1975): Eucleation of the eyeball In M. Joseph Bojrab's Current Technique in Small Animal Surgery
- Latimer H.B(1951): Weight of the eyeballs in Guinea pigs Anat. Rec. Vol 110 (3): 349-357
- Lindow M (2001). The Landmines-Sniffing Rats of the Mozambique. Time Magazine. Retrieved on 2008-06-23
- Olopade, J.O. and Onwuka S.K (2003): A preliminary investigation into some aspects of the craniofacial indices of the Red Sokoto (Maradi) goat in Nigeria. Folia Veterinaria 47(2): 57-59
- Olopade J.O., Onwuka S.K., Balogun, B.O., and Oke B.O (2005): Morphometric investigations of the brain of the West African Dwarf Sheep in Nigeria, Int J. Morphol, 23: 99-104
- Olopade, J.O (2006): Morphometric analysis of the skulls of three breeds of goats in Nigeria. PhD thesis in the Department of Veterinary Anatomy, University of Ibadan.
- Olopade, J.O. and Onwuka S.K (2009):Morphometric analysis of the skull of the Sahel goat breed: basic and clinical anatomy, Ital J Anat Embryol. 114(4):167-78.
- Olude, M.A. Craniomorphometric measurements of the skull of the African giant rat (*Cricetomys gambianus*, Waterhouse). Masters Dissertation in the department of Veterinary Anatomy, University of Ibadan (2009).
- Olude M.A., Olopade J.O., Fatola I.O. and Onwuka S.K. (2009) Some aspects of the neuro-

- craniometry of the African giant rat (*Cricetomys gambianus* Waterhouse). *Folia Morphol.* Vol. 68, 224–227
- Olude, M.A and Olopade, J.O (2010): Morphometric Studies of the Axial Skeleton of the African Giant Rat (*Cricetomys gambianus*, Waterhouse) Part (1): Skull Typology. *J. Vet. Anat.* 3, 1-12.
- Onar, V (1999): Morphometric study of the skull of the German Shepherd Dog (Alsatian). *Anat. Histol. Embryol.*, 28: 253-256
- Onar, V., Ozcan, S. and Pazvant, G (2001): Skull typology of the Adult male Kangal Dog. *Anat. Hist. Embryol* 30: 41-48
- Onyeanusu B.I., Adeniyi, A.A., Ayo J.O., Ibe C.S. and Onyeanusu C.G (2009): A comparative study of the urinary system of the African giant rat (*Cricetomys gambianus*, Waterhouse) and the Wistar rat. *Pakistan Journal of Nutrition* 8(7): 1043-1047
- Özkan, Z. E., G. Dýnç, A. Aydin (1997): Investigations on the comparative gross anatomy of scapula, clavícula, skeleton brachii and skeleton antebrachii in rabbits (*Oryctolagus cuniculus*), guinea pigs (*Cavia porcellus*) and rats (*Rattus norvegicus*). *Fýrat Un. J. Health Sci.* 11: 171-175.
- Özkan, Z. E (2005): Macro anatomy of axiale skeleton of hedgehog. *Ind. Vet. J.* 82: 877-882.
- Özkan Z.E (2007): Macro-anatomical investigations on the forelimb skeleton of mole-rat (*Spalax leucodon* Nordmann) *Veterinarski Arhiv* 72
- Smith C.J.D (1976): Gross anatomical and microscopic observations on the orbit and its content in *Notomys alexis* *Aust. J. Zool* 24: 479-89
- Yilmaz , S (1998): Macro-anatomical investigations on the skeletons of porcupine (*Hystrix cristata*) Part III: Skeleton axiale. *Anat. Hist. Embryol.* 27: 293-296.
- Zhou, G. and Williams, R.W. (1999): Mouse models for the analysis of myopia: an analysis of variation in eye size of adult mice. *Optom Vis Sci.* 76(6): 408-418

Acknowledgements

Thanks to Miss Ayeloja Salmot and Mr. Ogunbunmi Temitope. DVM V Students of the Federal University of Agriculture, Abeokuta.

Table (1) Showing measurements of parameters on the eyeball and the bony orbit of the African Giant Rat

PARAMETER	OVERALL MEAN	FEMALE	MALE
LOL (cm)	2.10 ± 0.03	2.05 ± 0.04	2.16 ± 0.04
ROL (cm)*	2.09 ± 0.02	2.05 ± 0.19	2.13 ± 0.03
LOC (cm)	5.74 ± 0.09	5.75 ± 0.13	5.94 ± 0.11
ROC (cm)	5.84 ± 0.09	5.58 ± 0.11	5.91 ± 0.13
LOH (cm)*	1.23 ± 0.03	1.16 ± 0.02	1.30 ± 0.03
ROH (cm)*	1.21 ± 0.03	1.16 ± 0.02	1.28 ± 0.04
ZGW (cm)	2.73 ± 0.05	2.71 ± 0.04	2.75 ± 0.10
ICD (cm) *	0.93 ± 0.03	0.85 ± 0.02	1.01 ± 0.02
RIO (cm)	0.75 ± 0.02	0.74 ± 0.03	0.76 ± 0.02
LIO (cm)	0.75 ± 0.02	0.74 ± 0.03	0.76 ± 0.02
LEW (gm)	0.16 ± 0.01	0.15 ± 0.01	0.16 ± 0.01
REW (gm)	0.15 ± 0.00	0.14 ± 0.01	0.15 ± 0.01
LEC/ AP (cm)	2.23 ± 0.01	2.20 ± 0.00	2.25 ± 0.00
LEC/ ML(cm)	2.02 ± 0.06	2.14 ± 0.03	1.90 ± 0.11
REC/ AP (cm)	2.06 ± 0.04	1.93 ± 0.03	2.20 ± 0.00
REC/ ML(cm)	2.13 ± 0.03	2.05 ± 0.19	2.20 ± 0.04
ROI	0.58 ± 0.01	0.57 ± 0.01	0.60 ± 0.02
LOI**	0.58 ± 0.01	0.57 ± 0.01	0.60 ± 0.01

* Parameters ICD, LOH, ROH, ROL were statistically significant between the sexes $P < 0.05$

** LOI significantly correlated positively at 0.05 against ROI.

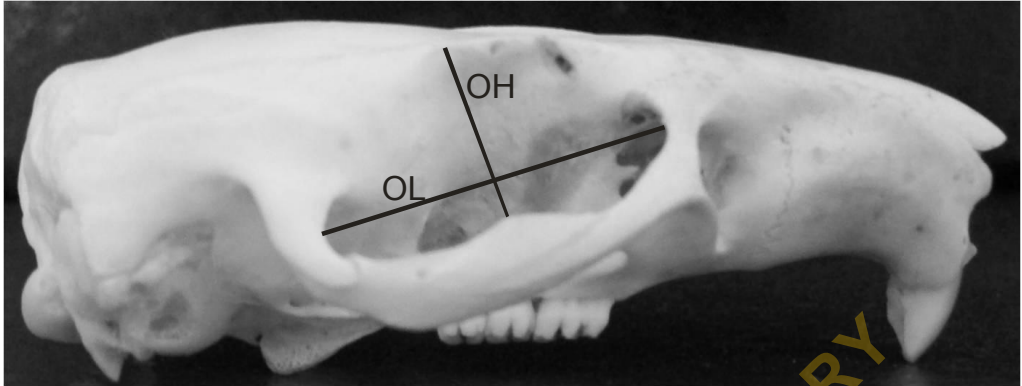


Fig (1): Outline of the lateral view of the skull of African Giant rat showing: OL bony orbital length; OH bony orbital height.

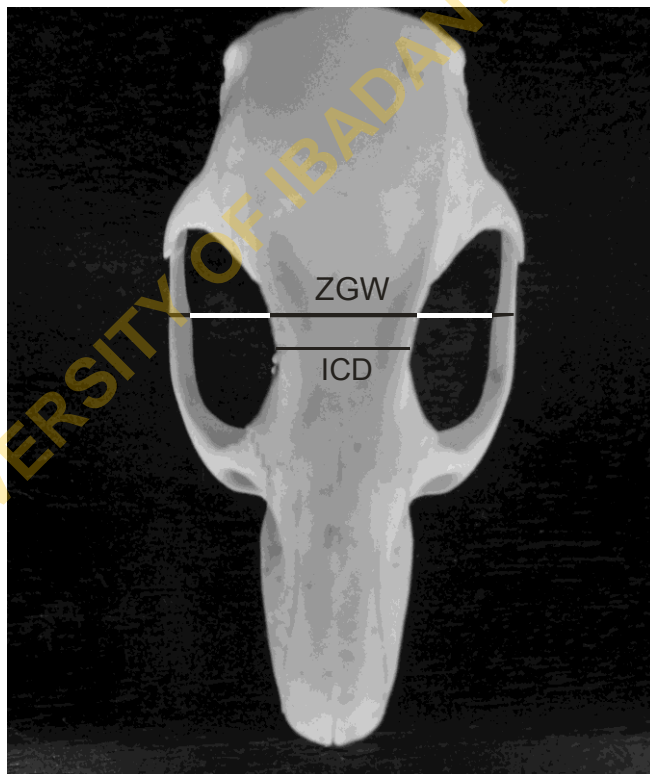


Fig (2): Outline of the dorsal view of the skull of African Giant rat showing: ICD intercanthi distance; ZGW zygomatic width distance.